Post TAVR Coronary Access With Evolut System

Jung-Min Ahn, MD., PhD.

University of Ulsan College of Medicine, Heart Institute,
Asan Medical Center, Seoul, Korea.

Common Pathophysiology

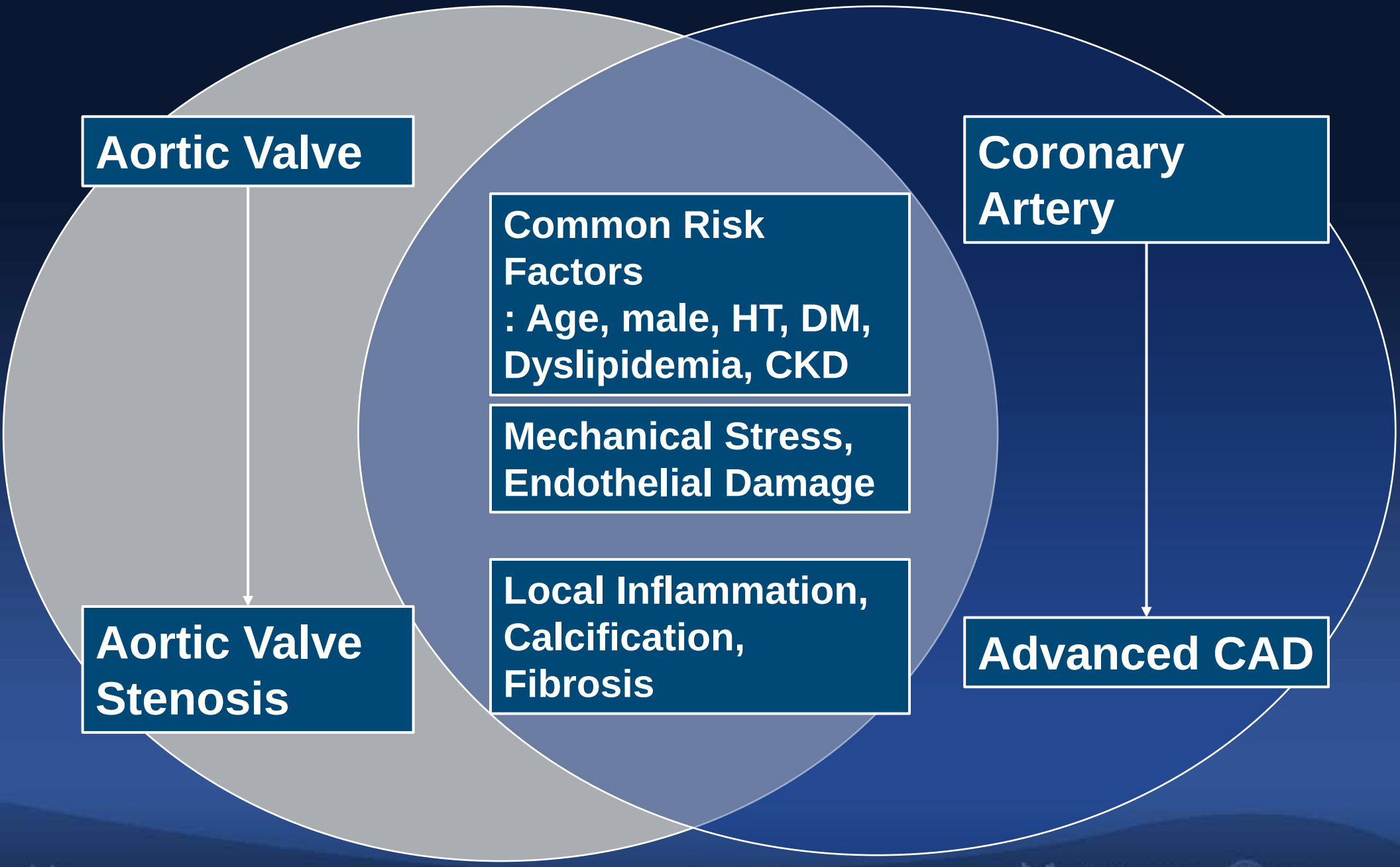

Milin AC et al, J Am Heart Assoc. 2014 Sep;5:e001111

CardioVascular Research Foundation
UNIVERSITY OF ULSAN COLLEGE MEDICINE
ASAN Medical Center

Incidence of CAD in Severe AS

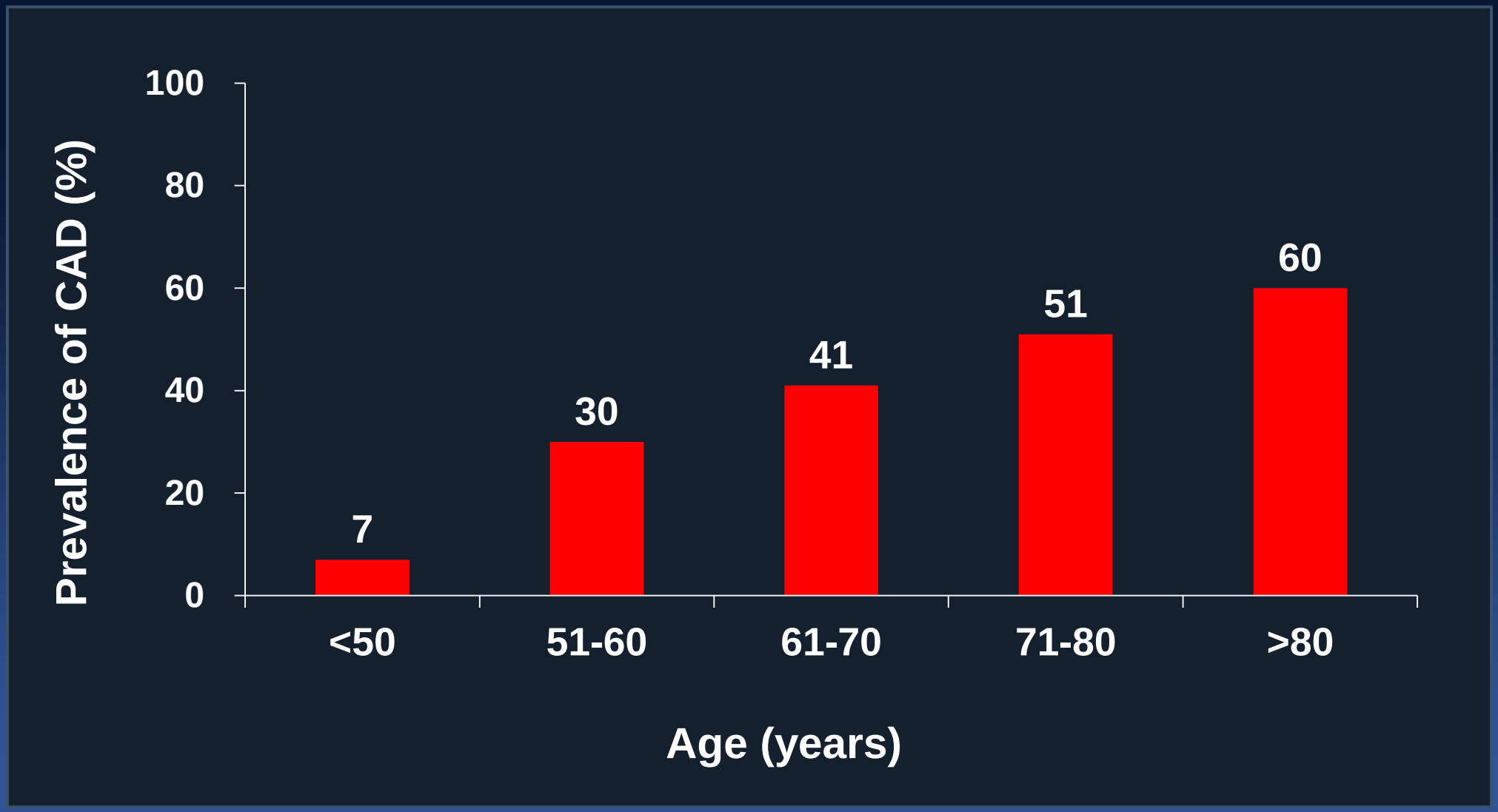

Stefanini GG et al, Eurointervention. 2013;9:S63-S68

Incidence of CAD in TAVR Patients

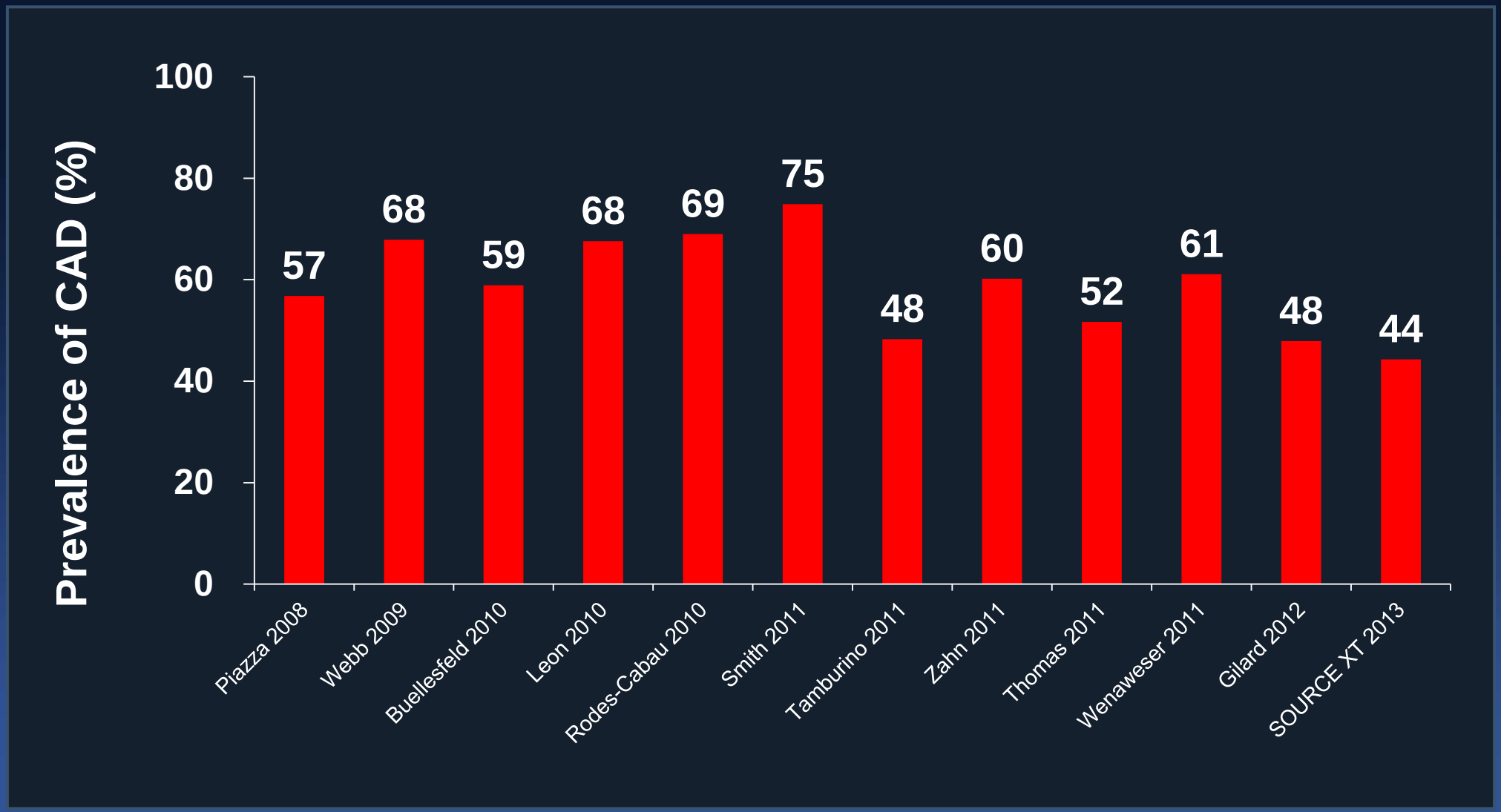

Stefanini GG et al, Eurointervention. 2013;9:S63-S68

Post TAVR PCI

	Kerckhoff-Klinik	Segeberg Registry	UK Registry	TAVR-LM Registry
Incidence	35 / 1,000 (**3.5%**)	17 / 296 (**5.7%**)	18 / 2,588 (**0.7%**)	9 / 6,405 (**0.1%**)
ACS Indication	11.4%	37.5%	65%	78%
Time to PCI	233 ± 158 days	17.7 months (range: 1-72)	136 days (range: 1-1092)	368 days (IQR: 204-534)
Type of TAV Implanted			Not Reported	
CoreValve	29%	100%		44%
SAPIEN XT	54%			55%
JenaValve	3%			
Symetis	11%			
Portico	3%			
Procedural Success	***74%***	***95.8%***	Not Reported	100%

[1]Blumenstein, et al., *Clin Res Cardiol* 2015; 104:632-39; [2]Allali, et al., *Cardiovasc Revasc Med* 2016; epub ahead of print; [3]Snow, et al., *Int J Cardiol* 2015; 199:253-60; [4]Chakravarty, et al., *J Am Coll Cardiol* 2016; 67:951-60

Coronary access after tavi

COREVALVE EVOLUT R FRAME GEOMETRY

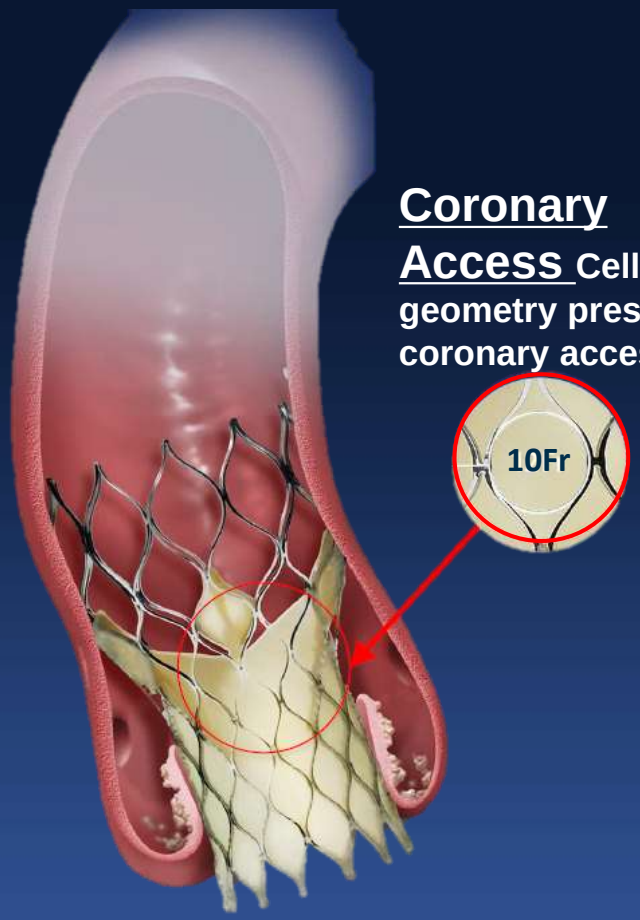

Coronary Access Cell geometry preserves coronary access

Skirt Height
(From inflow to center of Node 3)

Evolut R/PRO 23 ≈13mm | Evolut R/PRO 26 ≈13mm | Evolut R/PRO 29 ≈14mm | Evolut R 34 ≈14mm

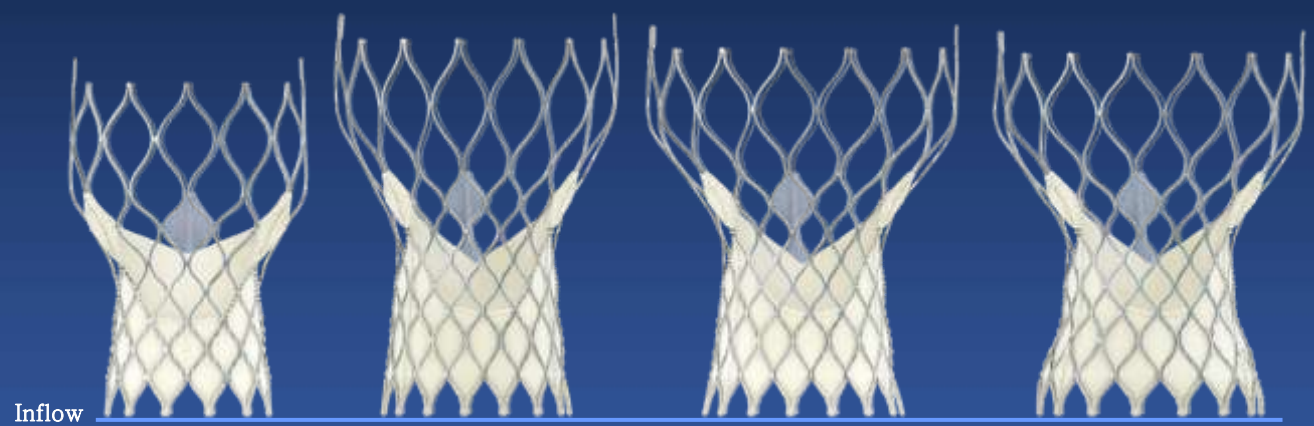

CoreValve Evolut 23 ≈12mm | CoreValve 26 ≈13mm | CoreValve 29 ≈13mm | CoreValve 31 ≈13mm

*Valves are not shown to scale

Coronary access after tavi

C-MARK AND COMMISSURE POSITION

- C-Mark of the paddle can provide the geometry of the commissures of the Evolut.

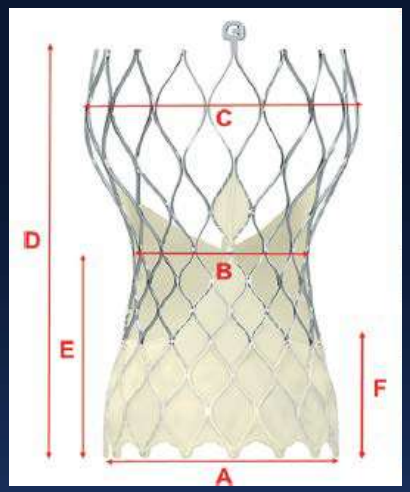

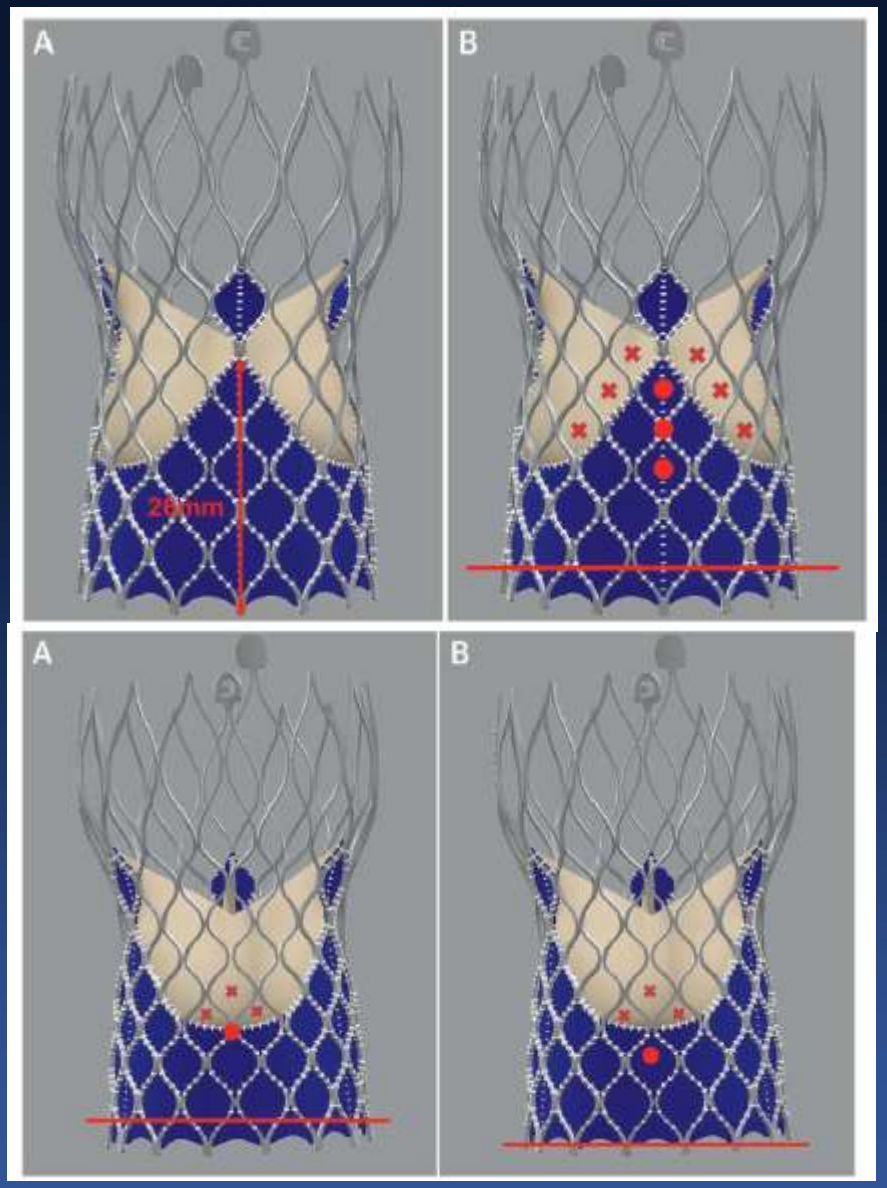

	23mm Evolut R / PRO	26 mm Evolut R / PRO	29mm Evolut R / PRO
A. Inflow Diameter	23 mm	26 mm	29 mm
B. Waist Diameter	20 mm	22 mm	23 mm
C. Outflow Diameter	34 mm	32 mm	34 mm
D. Frame height	45 mm	45 mm	45 mm
E. Commissure Height	26 mm	26 mm	26 mm
F. Skirt Height	13 mm	13 mm	13 mm

Matias B. Yudi MBBS et al. Coronary Angiography and Percutaneous Coronary Intervention After Transcatheter Aortic Valve Replacement

CASE (1)

- 78/F
- Effort chest pain
- P/MHx
  DM, HT
  NSTEMI s/p PCI at pLAD, pLCX (‘16.11.25)
  Rt. ICA stenosis
  Severe AS s/p TAVR (’16.11.29)
- STS score 2.359%

PCI Before TAVR (16.11.25)

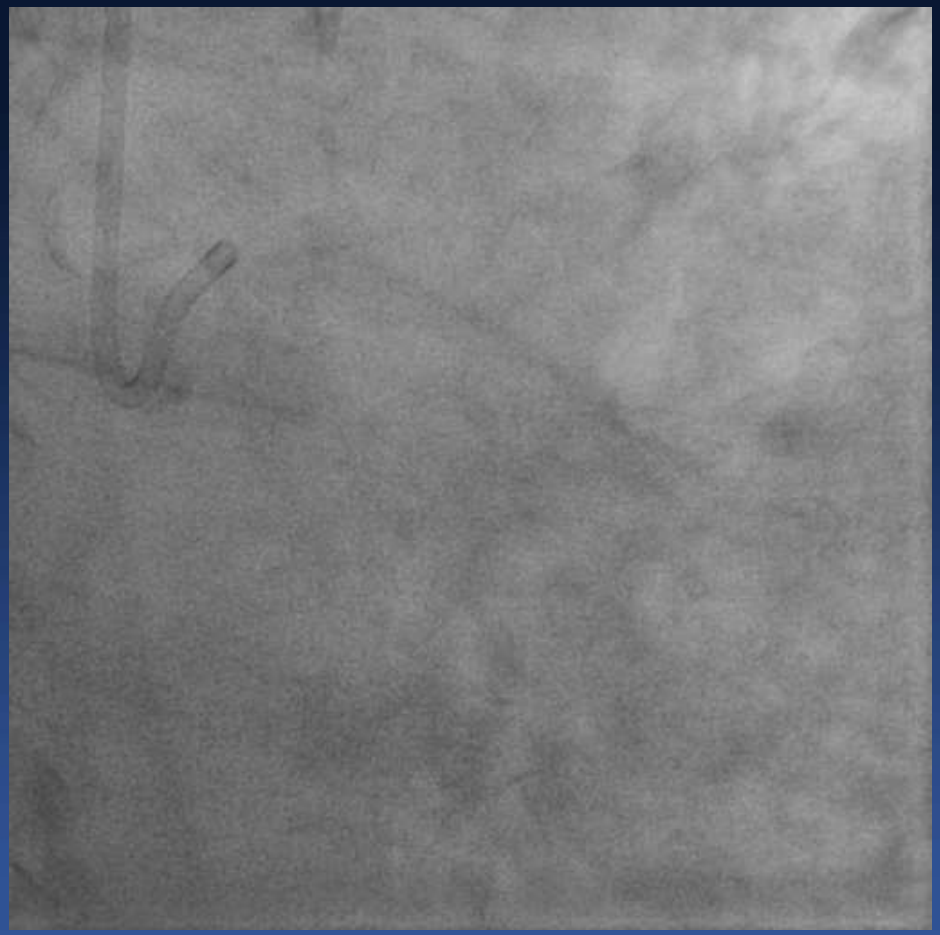

Stenosis at LM bifurcation

PCI Before TAVR (16.11.25)

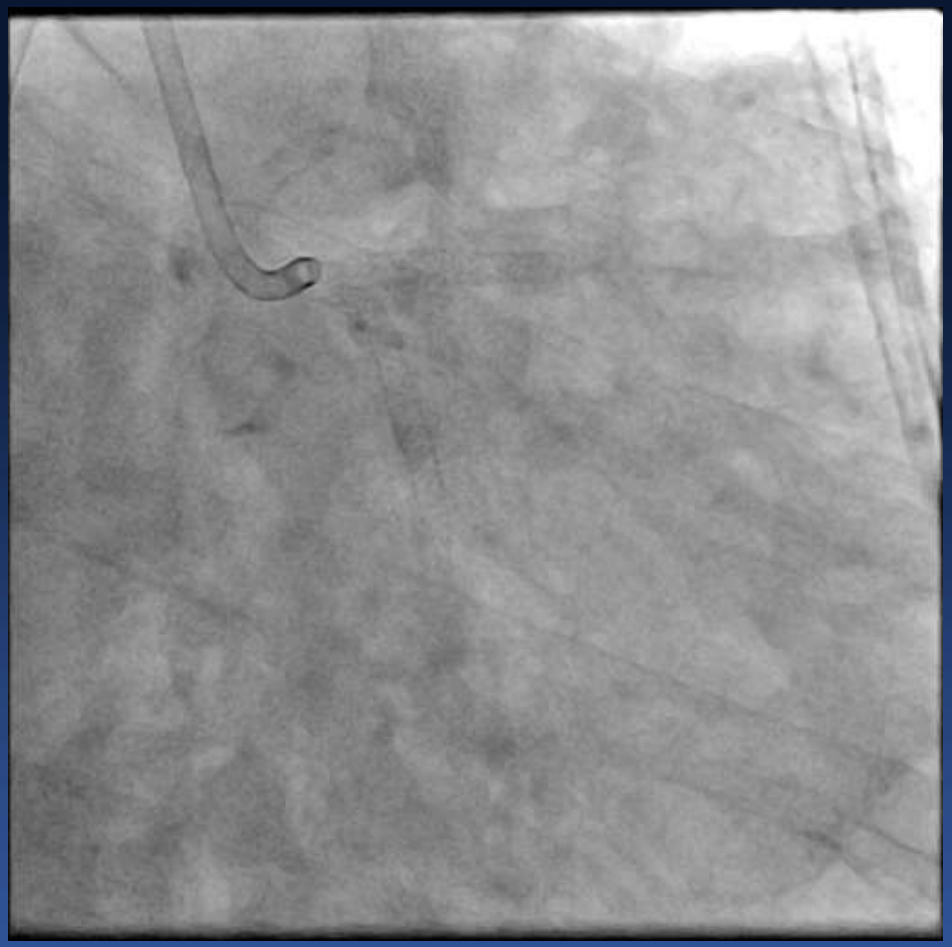

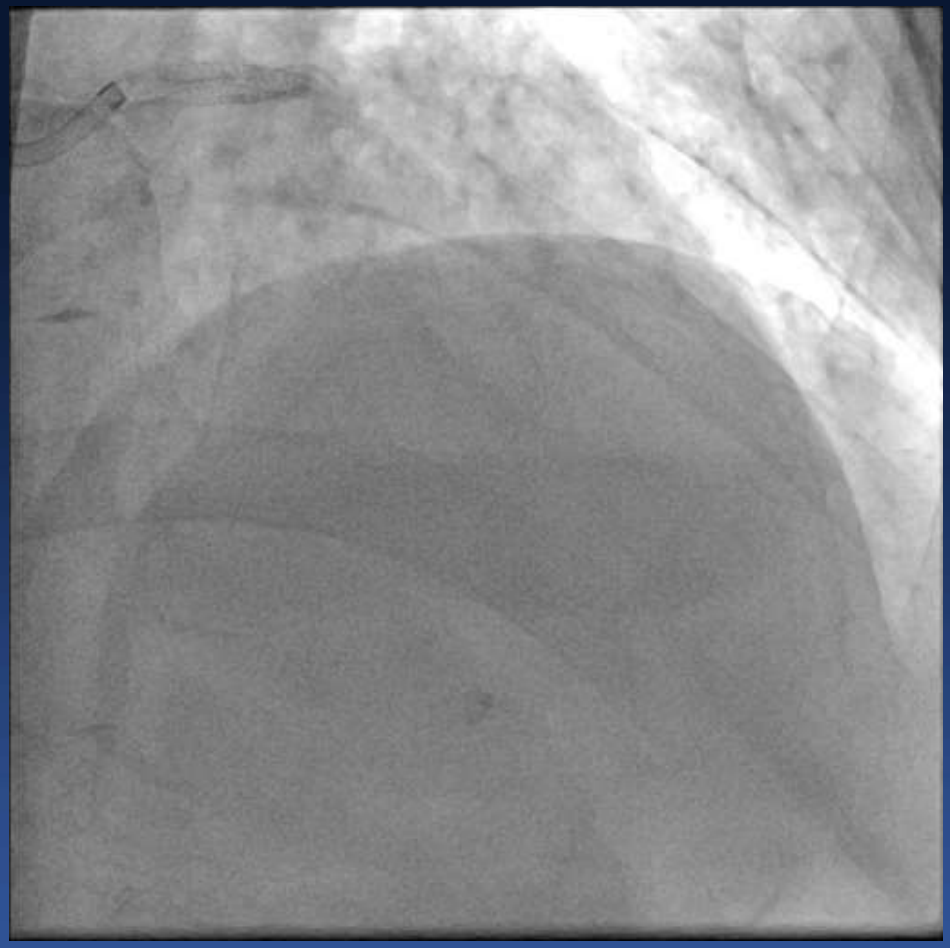

LM-pLAD Xience A 3.0 (28)
pLCX Xience A 2.5 (33)

CT findings – Aortic annulus view

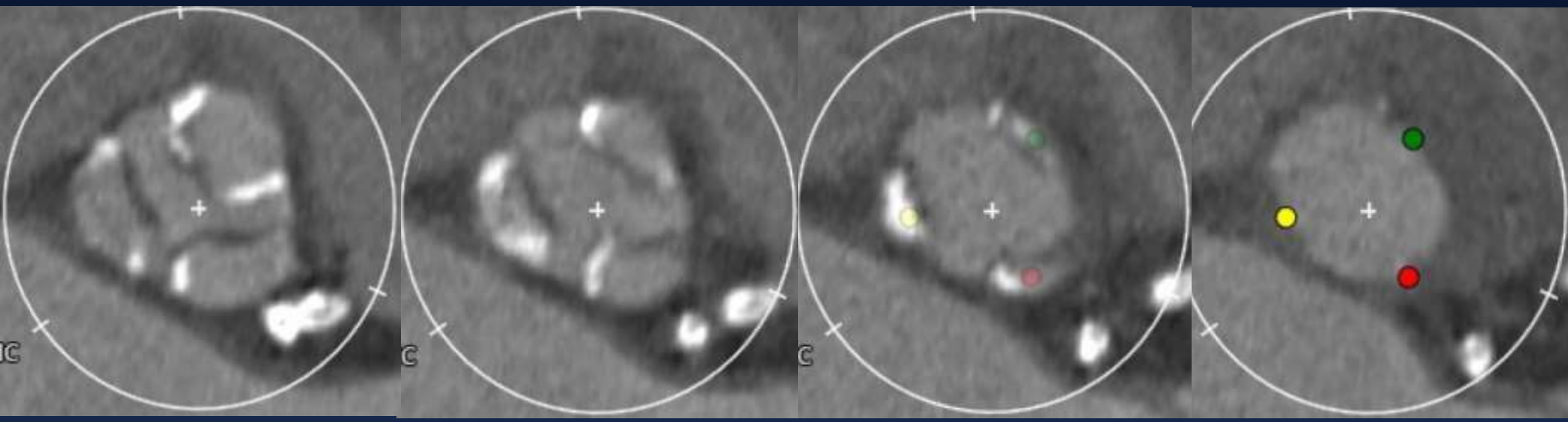

Annulus plane

Aortic Annulus parameters	
Annulus short diameter	19.0 mm
Annulus long diameter	24.1 mm
Annululs mean diameter	21.5 mm
Annulus area	369 mm^2
Annulus area-driven diameter	21.7 mm
Annulus perimeter	69.0 mm
Annulus perimeter-driven diameter	21.9 mm

CT findings – Aortic Valve Complex

Sinus of Valsalva

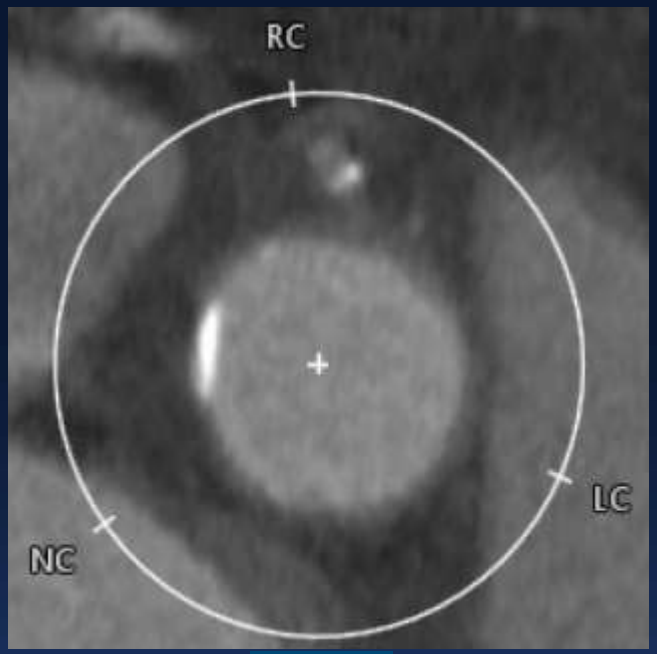

STJ

Sinus of Valsalva		STJ	
Area	640 mm^2	Area	504 mm^2
Sinus / Annulus Area Ratio	1.73	STJ/ Annulus Area Ratio	1.37
NCC diameter	28.7 mm	Mean diameter	25.5 mm
LCC diameter	27.8 mm		
RCC diameter	27.8 mm		

Mean Sinus / Annulus Area Ratio **1.83 ± 0.27** **Mean STJ / Annulus Area Ratio** **1.49 ± 0.29**

CT findings – Aortic Valve Complex

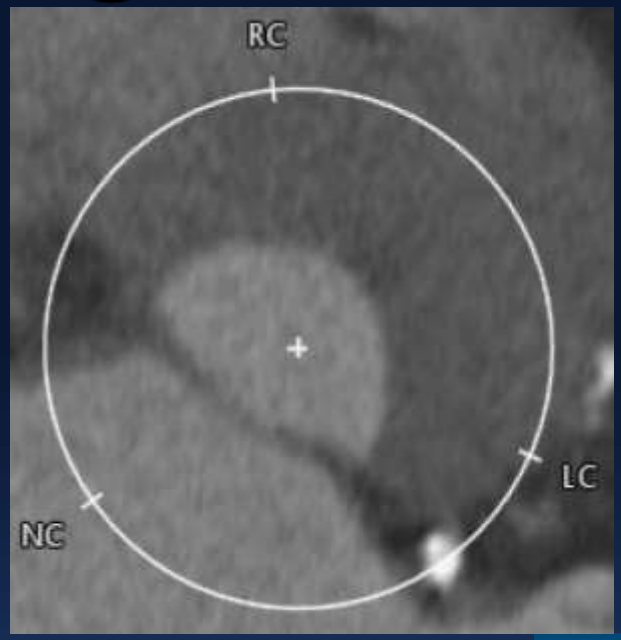

LVOT

LVOT	
Area	323 mm^2
LVOT / Annulus Area Ratio	0.88
Short diameter	16.6 mm
Long diameter	24.7 mm

Mean LVOT / Annulus Area Ratio **0.95 ± 0.12**

CT findings – Aortic Valve Complex

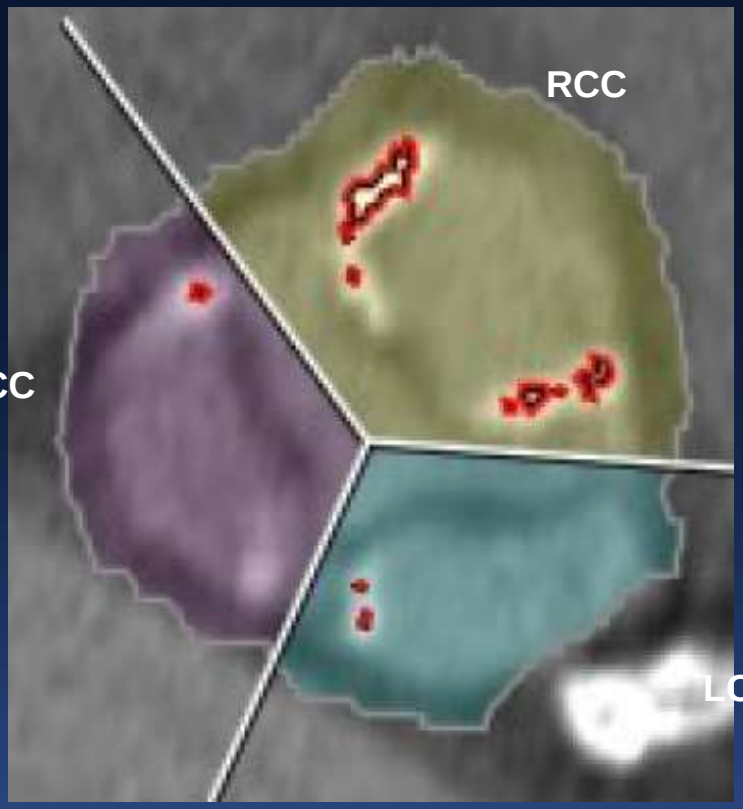

Calcium volume	
NCC	50 mm^3
RCC	53 mm^3
LCC	27 mm^3
Total	130 mm^3

CT findings – Coronary Height

Coronary Height	
LCA	9.2 mm
RCA	16.2 mm

TAVR ('16.11.29)

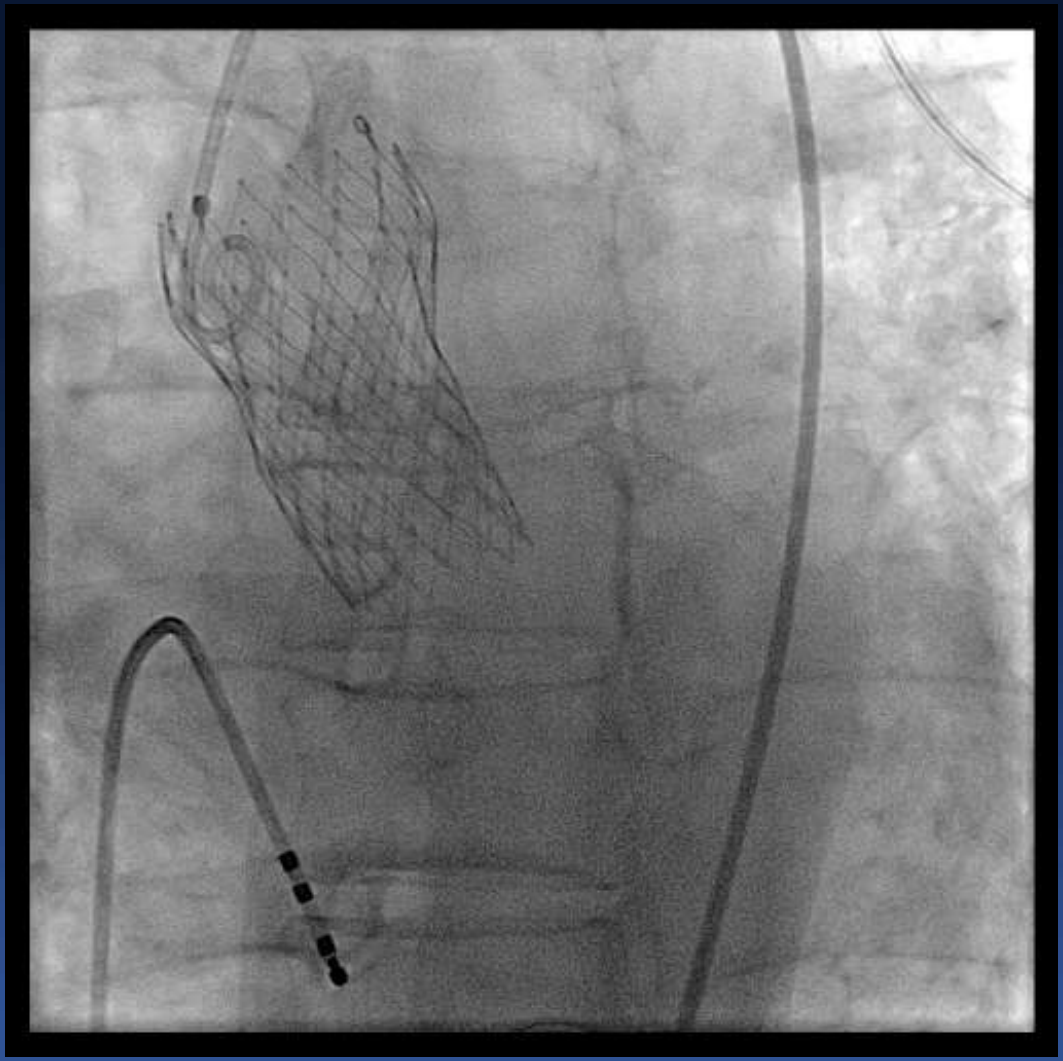

Evolut R 26 mm

Chest Pain

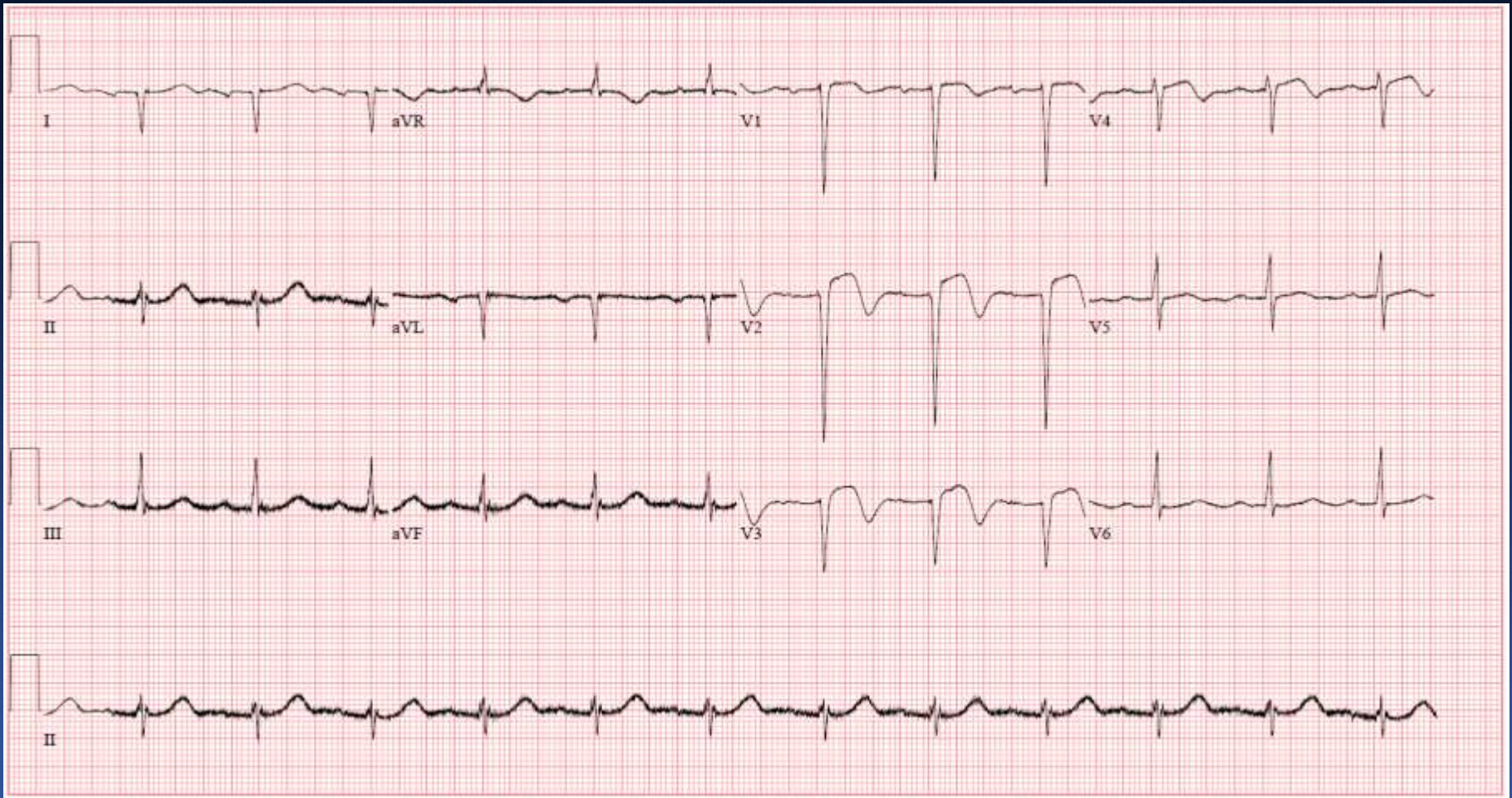

Coronary angiogram

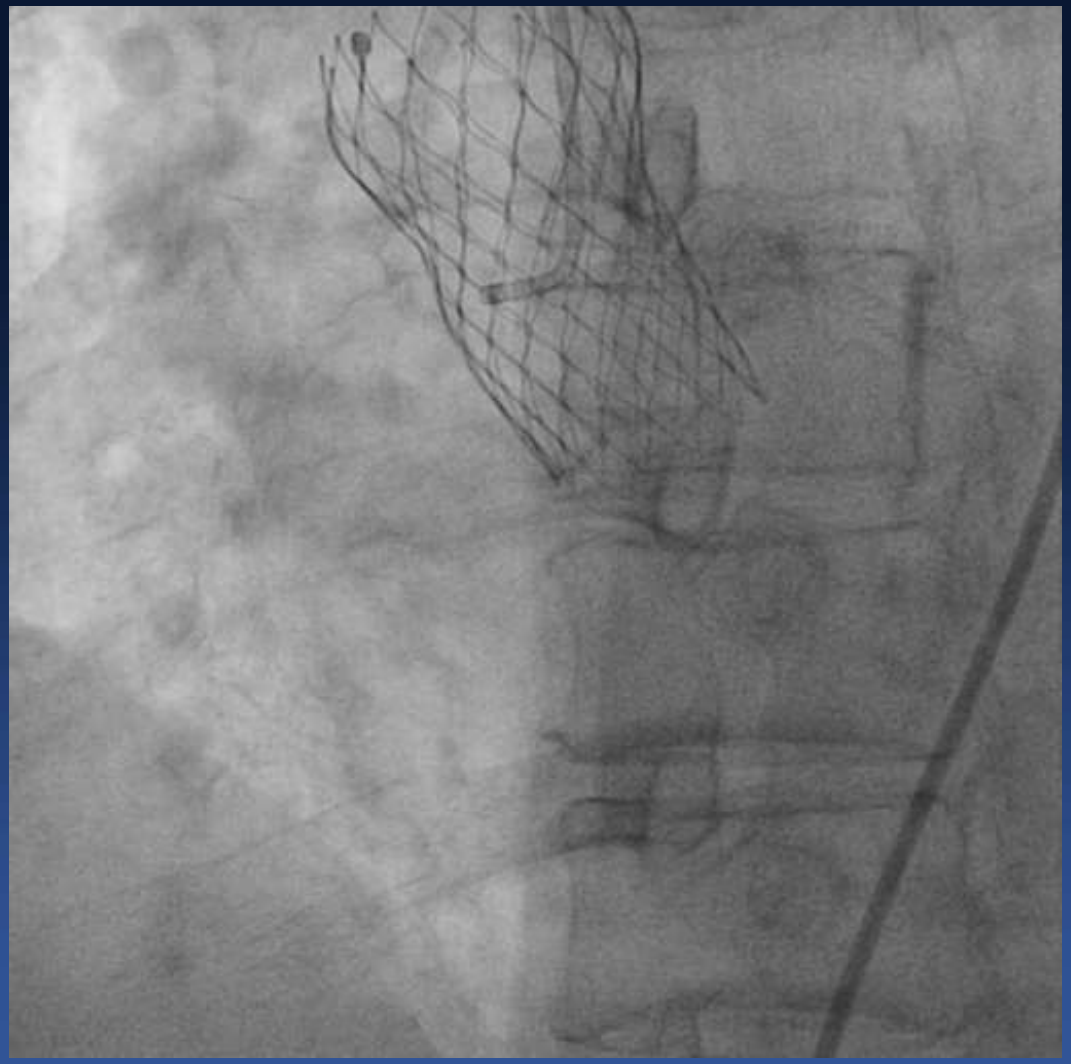

We couldn’t engage LCA

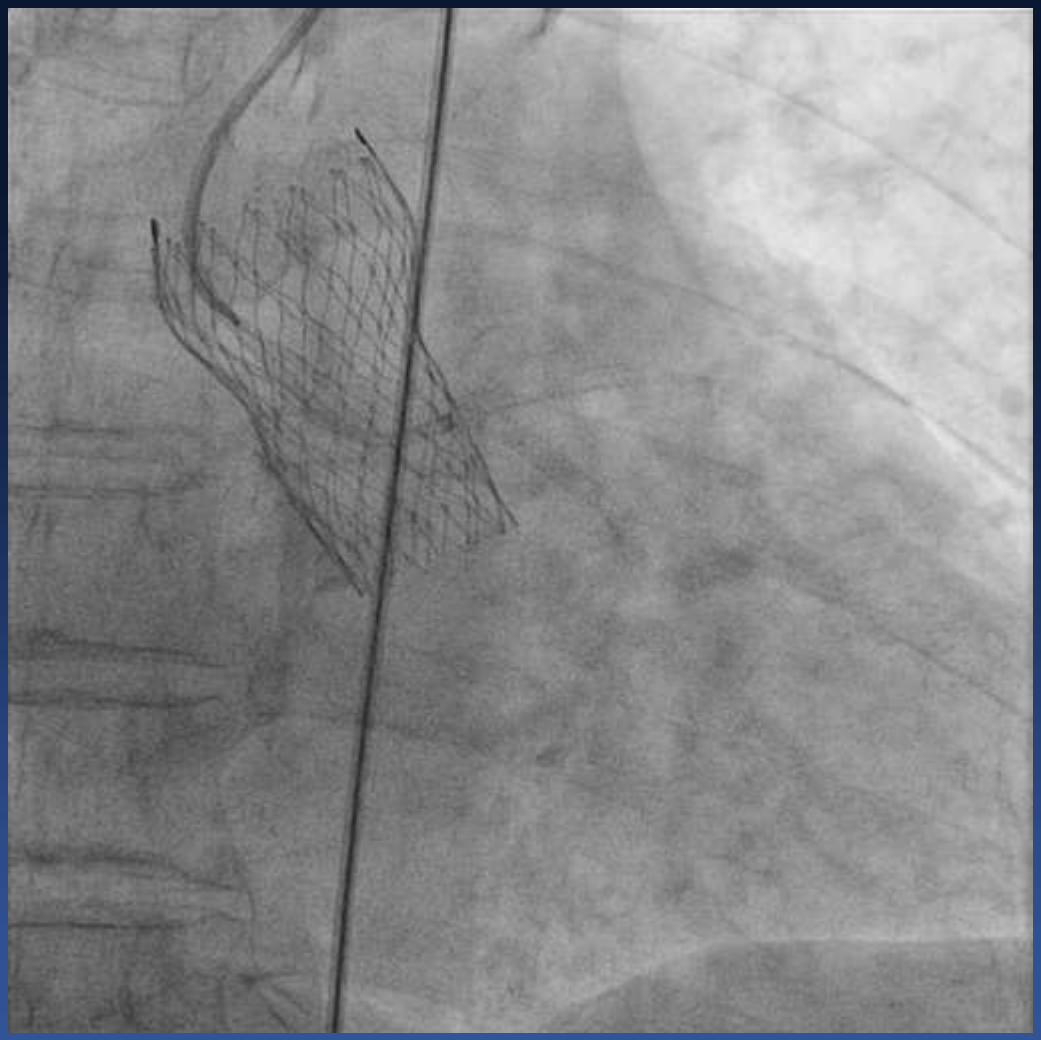

Aortogram

Filling defect at pLAD stent

Suspected Stent Thrombosis

80 YO Female, 4months after TAVR and PCI

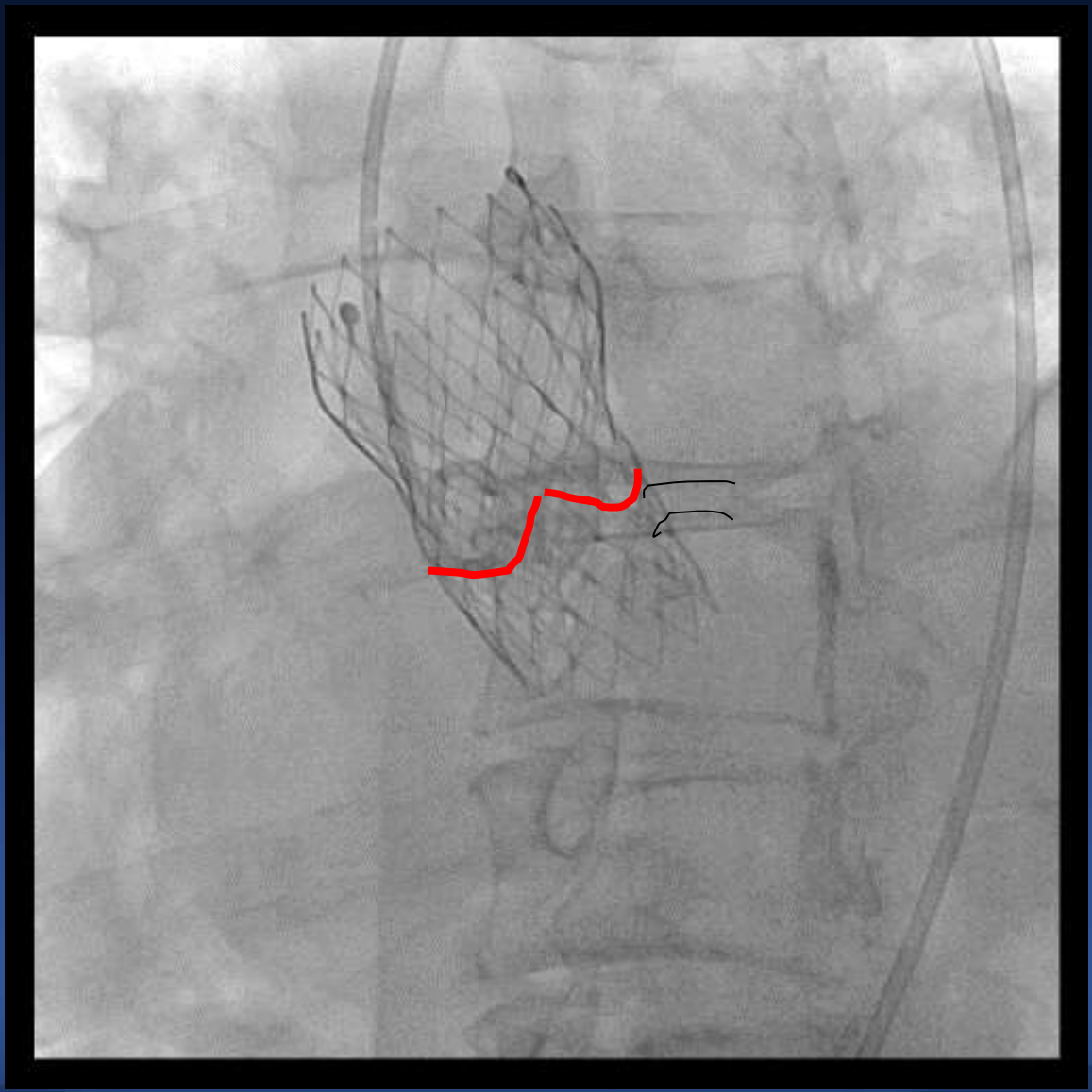

CASE (2)

- 71/F
- DOE (NYHA Fc II)
- P/MHx
  DM, HT
  s/p PCI at pmRCA (‘13.4.3)
  Carotid artery stenosis s/p stenting (‘19.3.19)
  Severe AS s/p TAVR (’19.4.28)
- STS score 3.878%

CAG Before TAVR (19.3.23)

CAG Before TAVR (19.3.23)



CT findings – Aortic annulus view

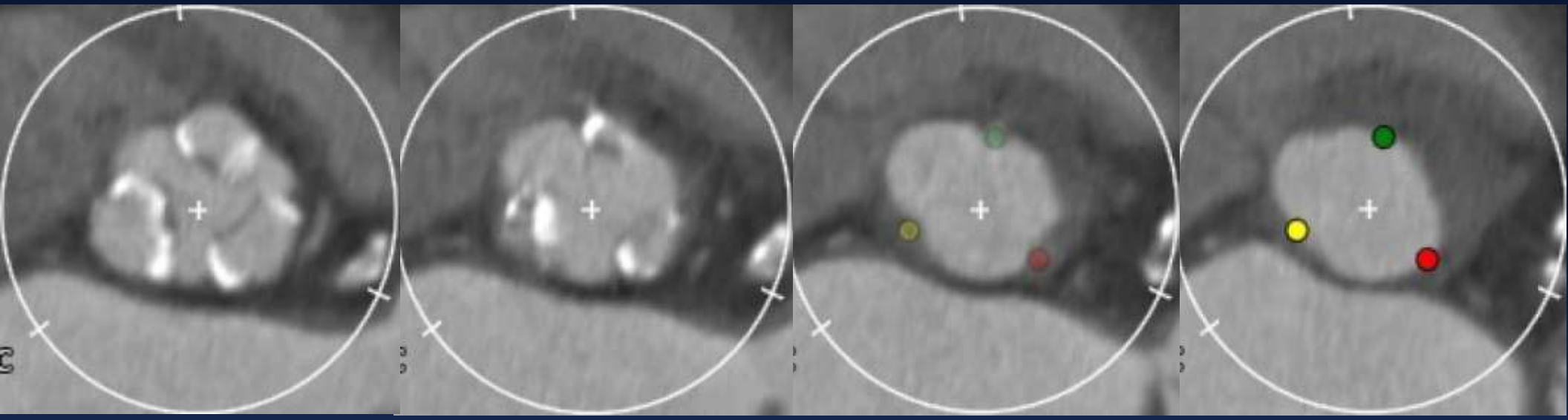

Annulus plane

Aortic Annulus parameters	
Annulus short diameter	17.3 mm
Annulus long diameter	23.1 mm
Annulus mean diameter	20.2 mm
Annulus area	304 mm^2
Annulus area-driven diameter	19.7 mm
Annulus perimeter	62.9 mm
Annulus perimeter-driven diameter	20.0 mm

CT findings – Aortic Valve Complex

Sinus of Valsalva

STJ

Sinus of Valsalva		STJ	
Area	517 mm^2	Area	463 mm^2
Sinus / Annulus Area Ratio	1.70	STJ/ Annulus Area Ratio	1.52
NCC diameter	26.8 mm	Mean diameter	24.3 mm
LCC diameter	25.4 mm	Height of STJ	19.3 mm
RCC diameter	24.9 mm		

Mean Sinus / Annulus Area Ratio **1.83 ± 0.27** **Mean STJ / Annulus Area Ratio** **1.49 ± 0.29**

CT findings – Aortic Valve Complex

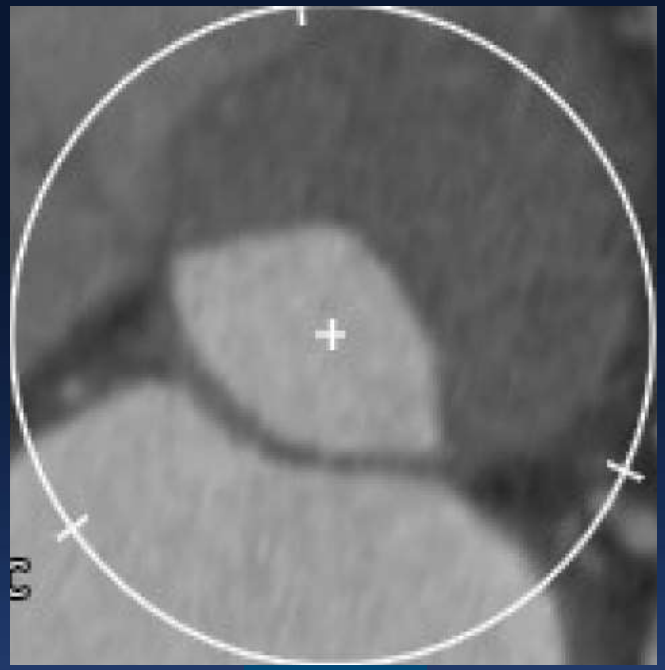

LVOT

LVOT	
Area	267 mm^2
LVOT / Annulus Area Ratio	0.88
Short diameter	15.5 mm
Long diameter	23.6 mm
Mean LVOT / Annulus Area Ratio	**0.95 ± 0.12**

CT findings – Aortic Valve Complex

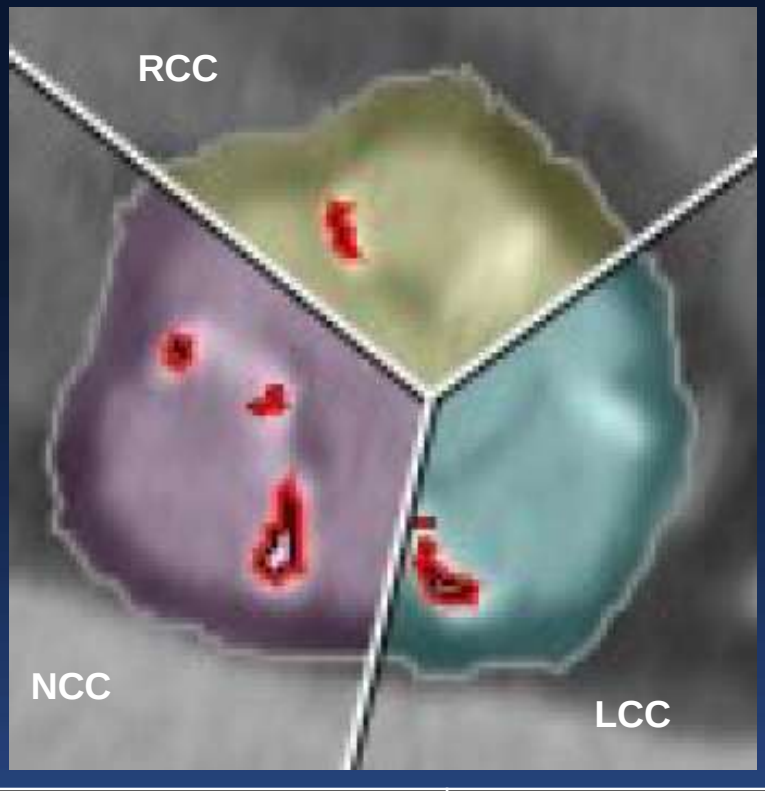

Calcium volume	
NCC	52 mm^3
RCC	61 mm^3
LCC	30 mm^3
Total	143 mm^3

Mean Amount of total Calcium 355.4 ± 289.9

CardioVascular Research Foundation
UNIVERSITY OF ULSAN COLLEGE MEDICINE
ASAN Medical Center

CT findings – Coronary Height

LCA

RCA

Coronary Height	
LCA	11.0 mm
RCA	15.2 mm

TAVR

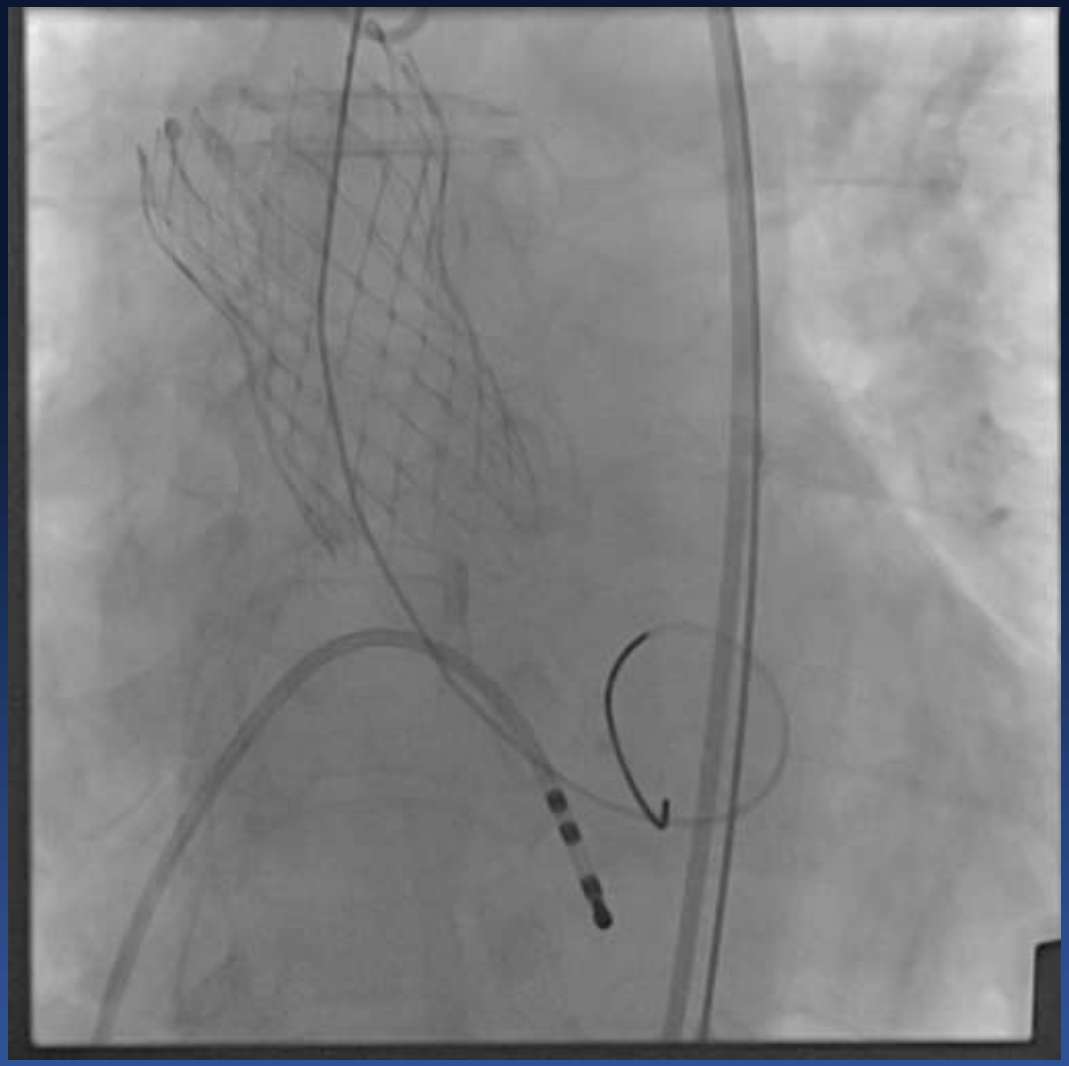

Evolut Pro 26 mm
Device Embolization after deployment

CardioVascular Research Foundation
UNIVERSITY OF ULSAN COLLEGE MEDICINE
ASAN Medical Center

TAVR: Valve-in-Valve

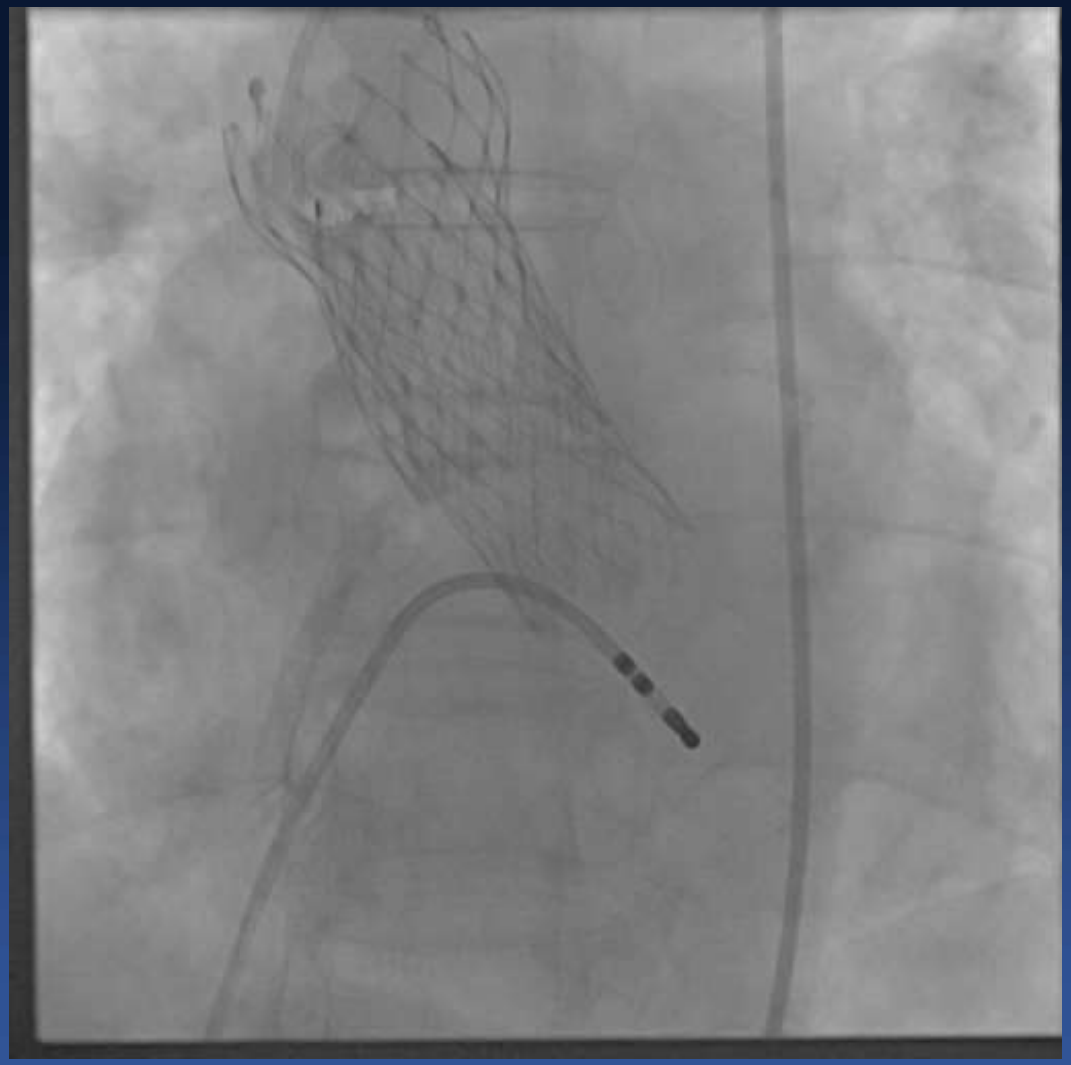

Evolut R 26 mm

Chest pain

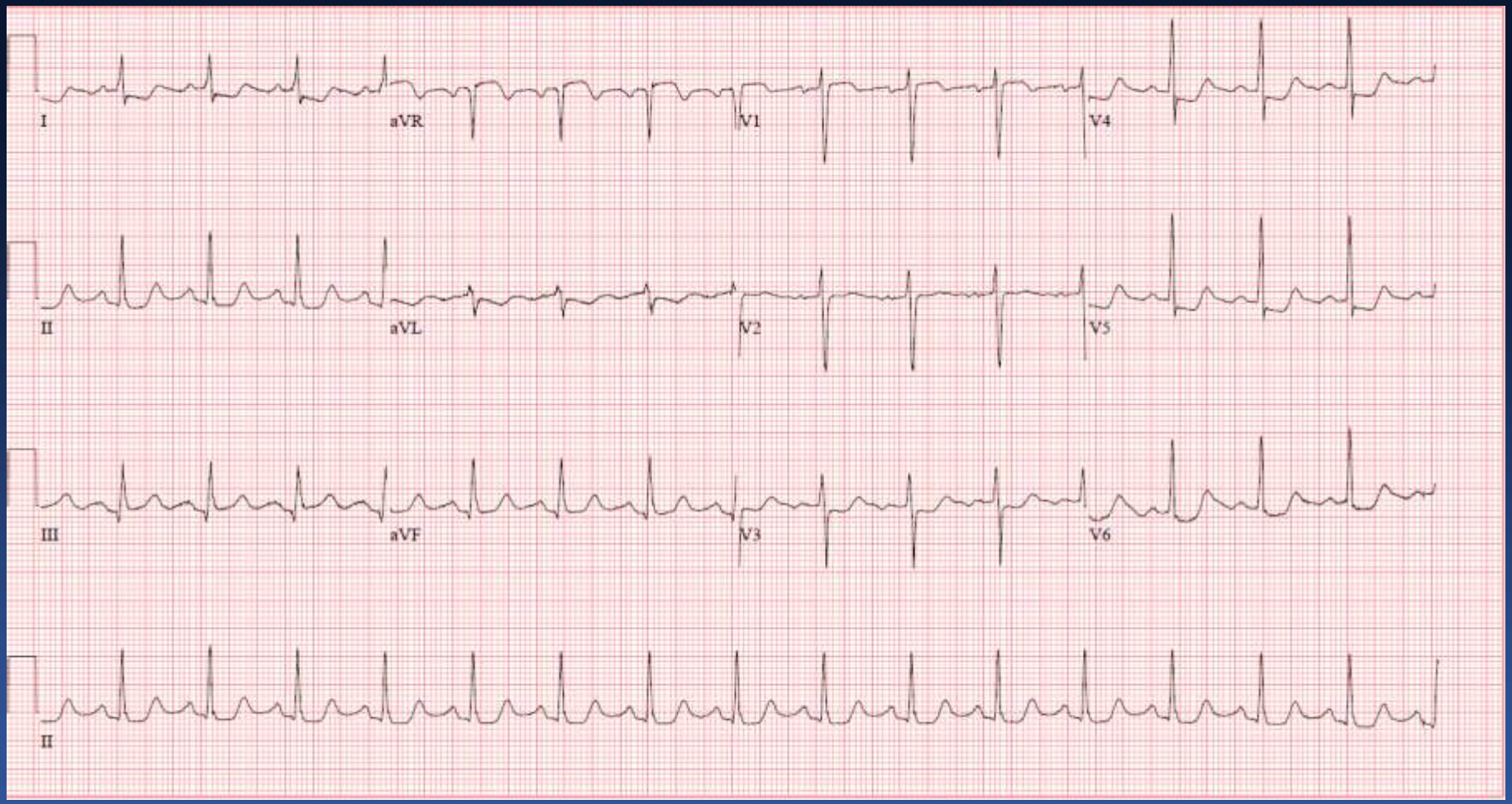

Troponin-I 5.973 ng/mL

Coronary angiogram

Coronary angiogram

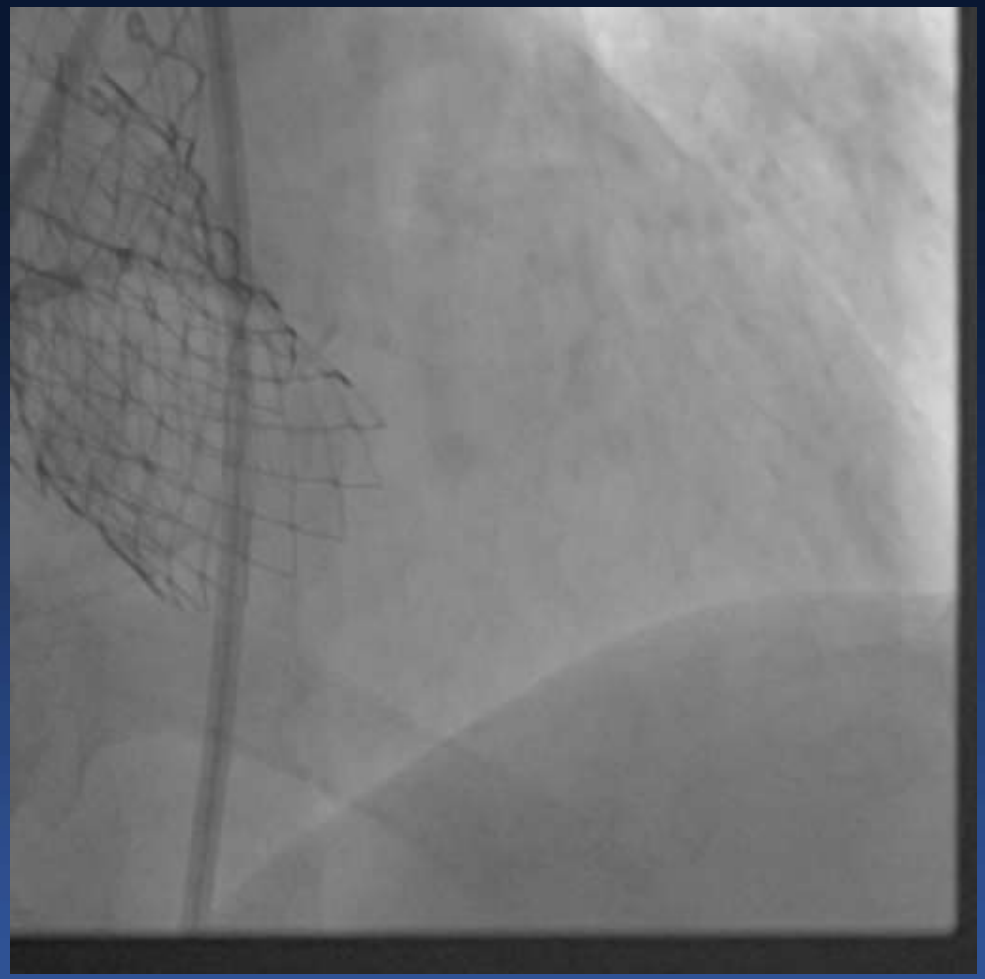

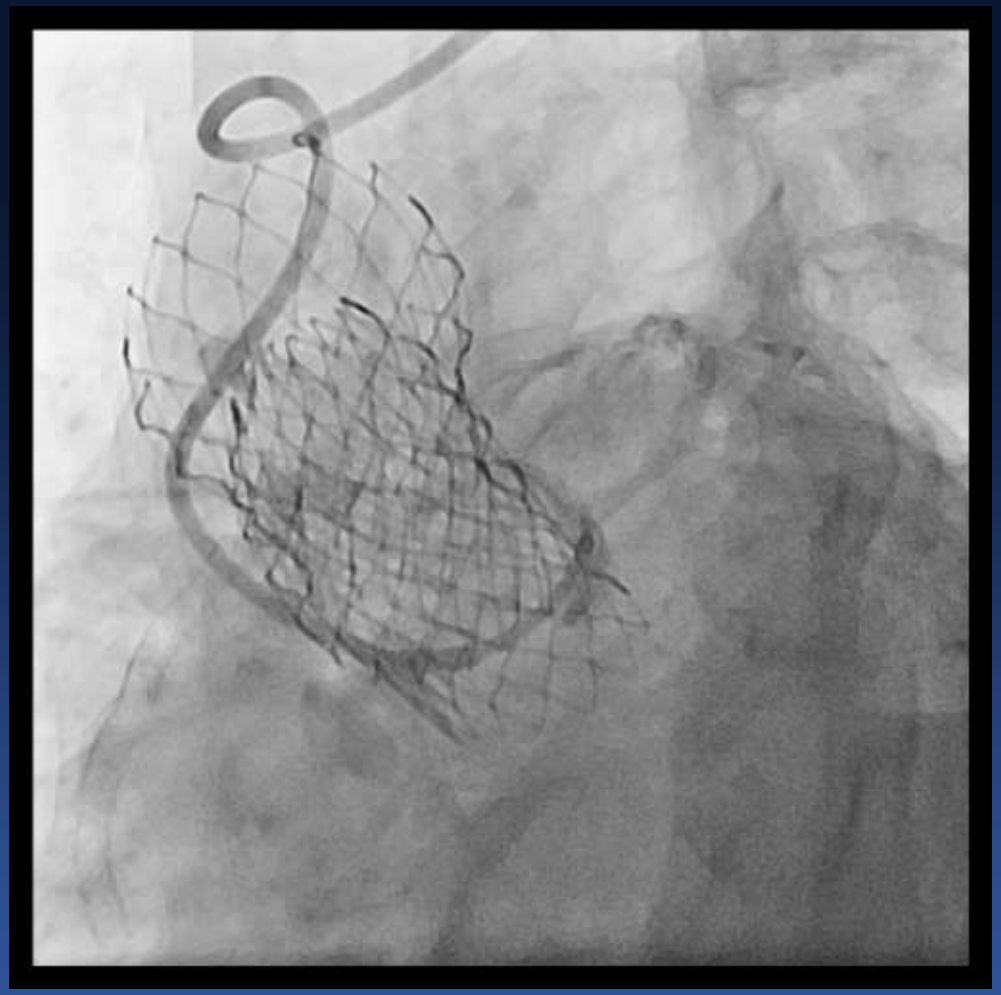

Engagement using Guidezilla

NSTEMI

?

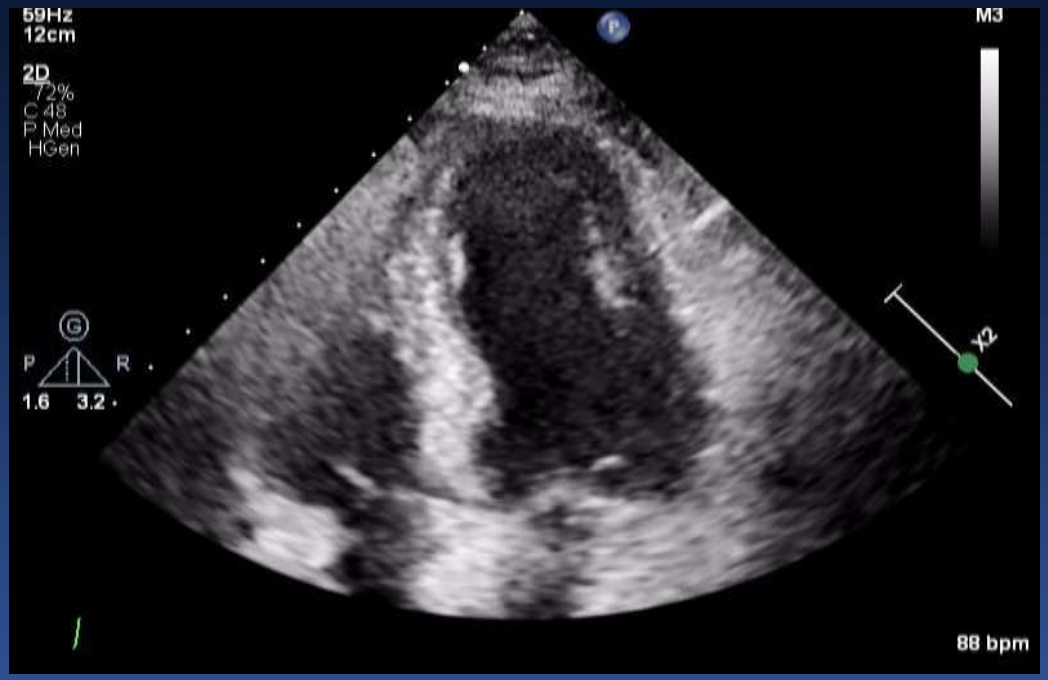

Blood Pressure in Sinus

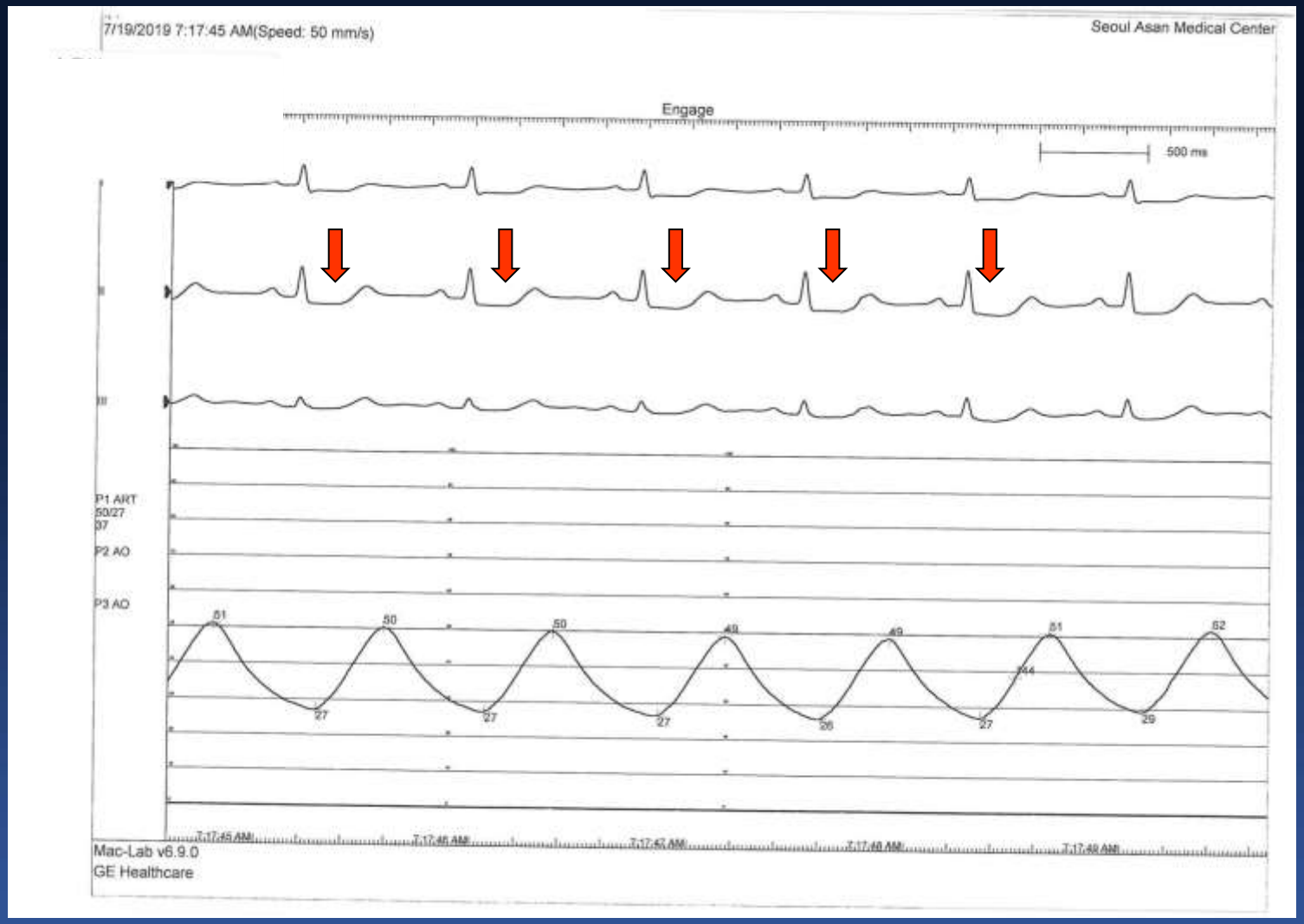

BP 50/27 mmHg in Sinus

Chimney technic
Releasing sinus obstruction

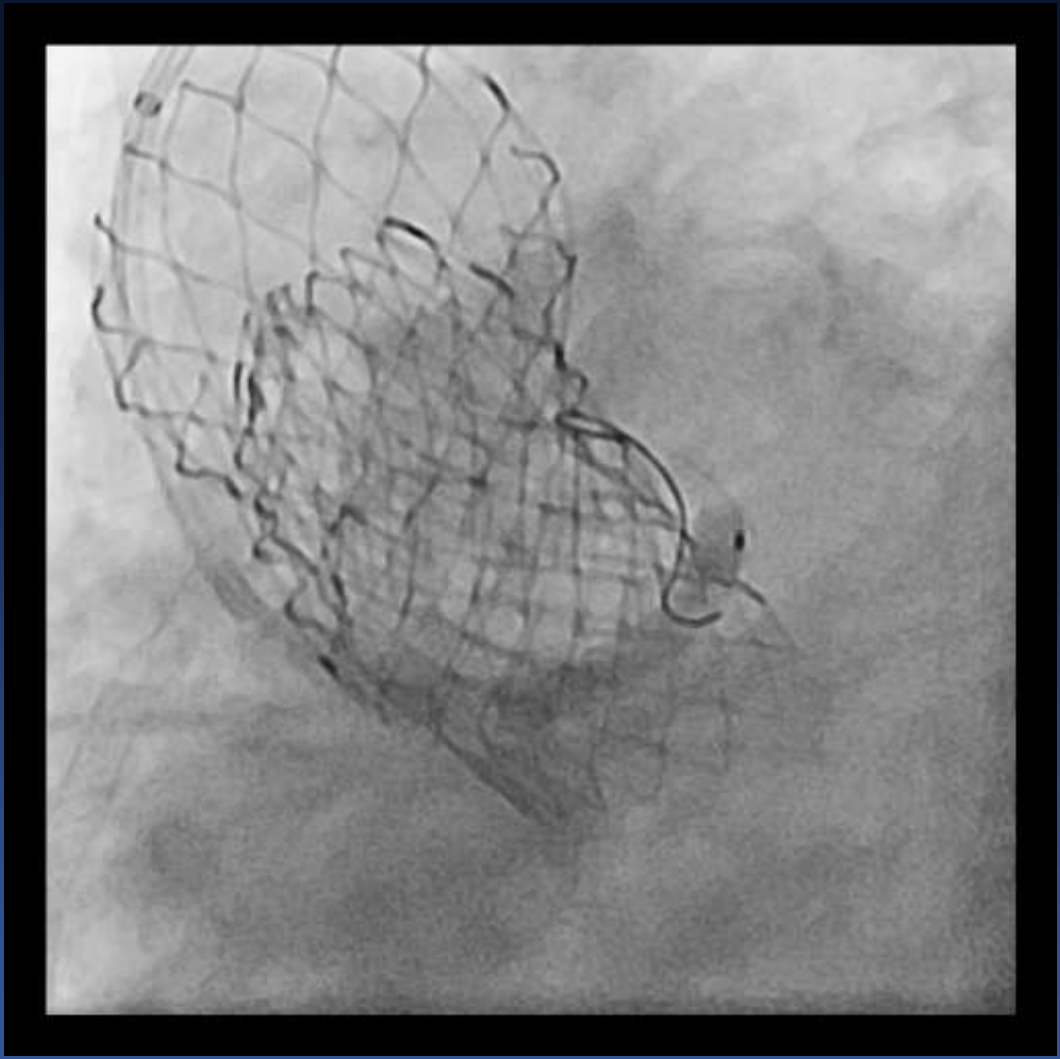

Xience S 4.0 (38)

Post NC balloon

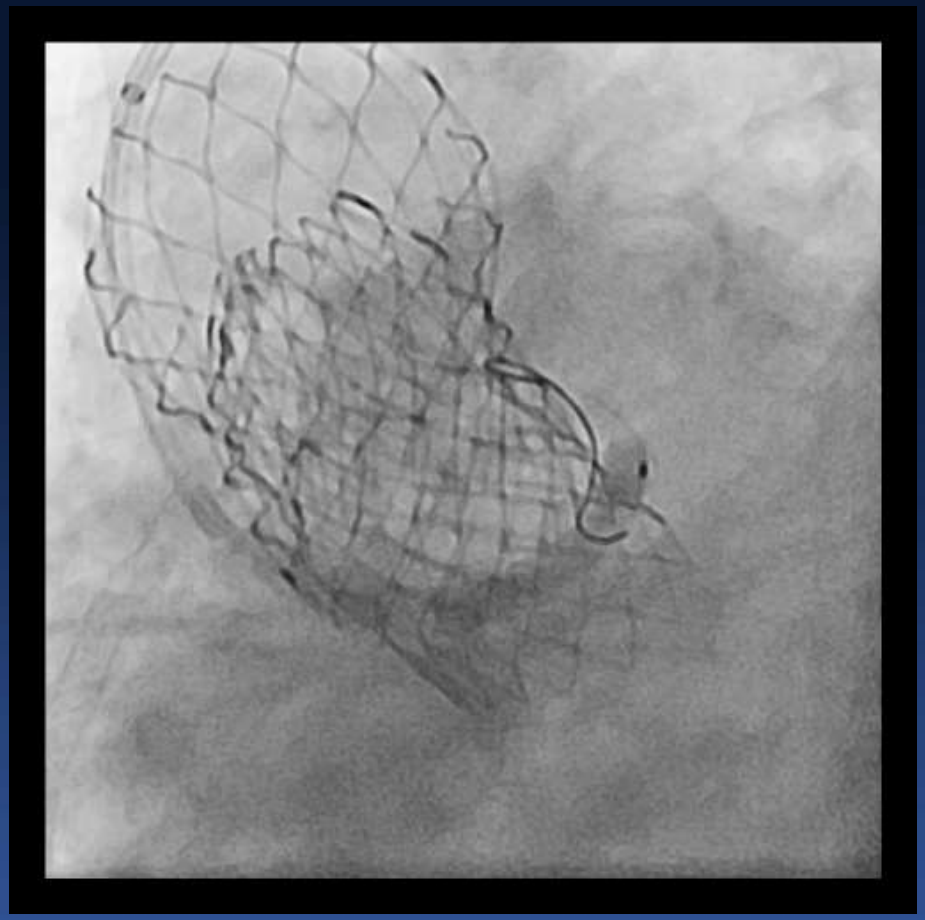

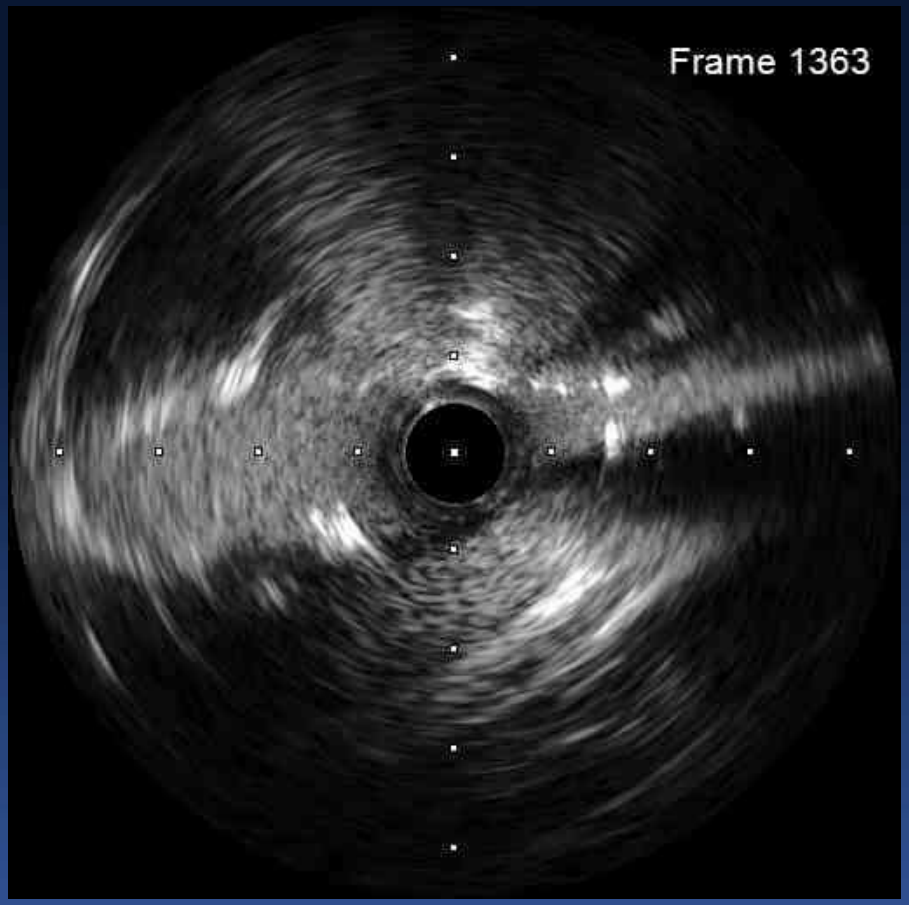

MSA 6.4 mm^2

Stent overlap for enough lumen

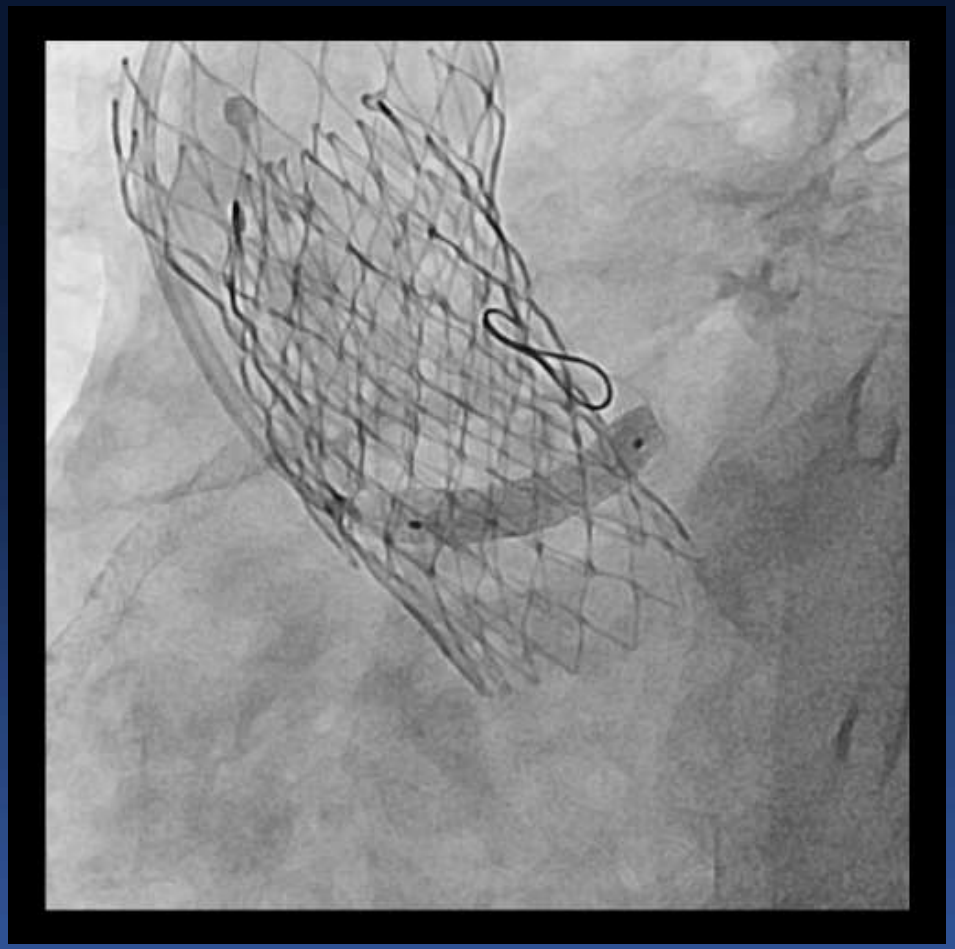

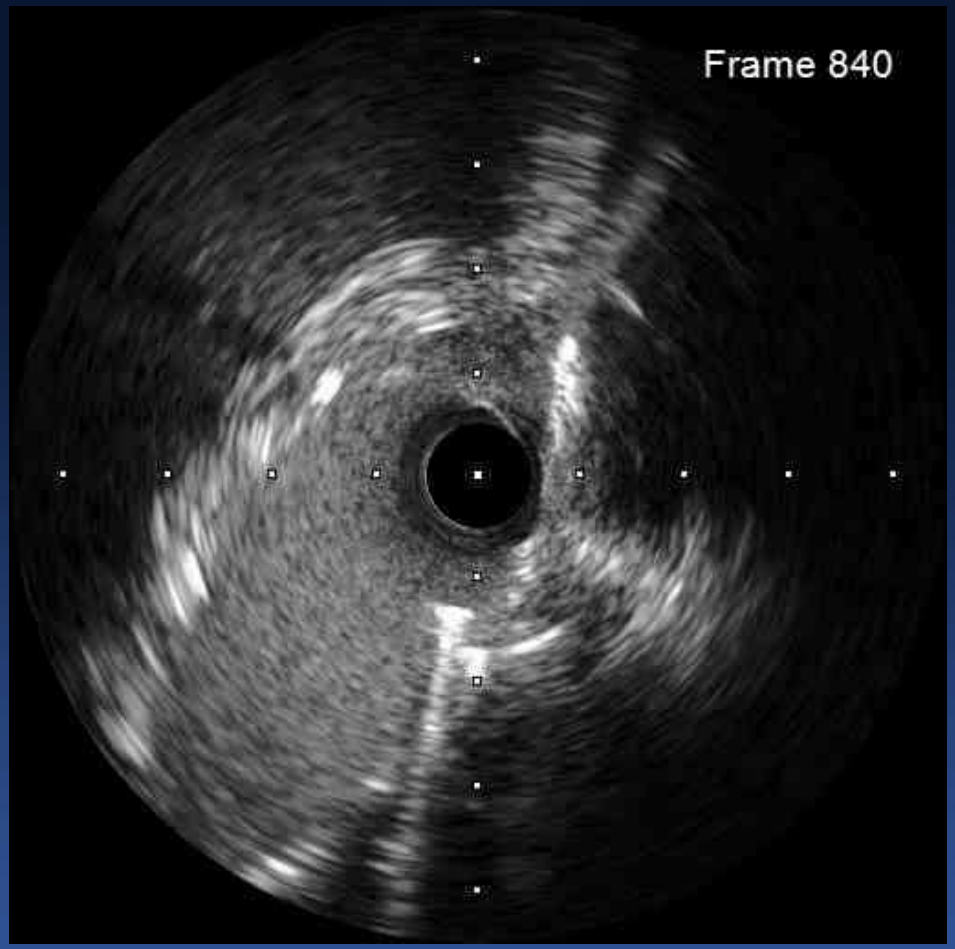

Xience S 4.0 (23)
MSA 10.6 mm^2

Final coronary angioram

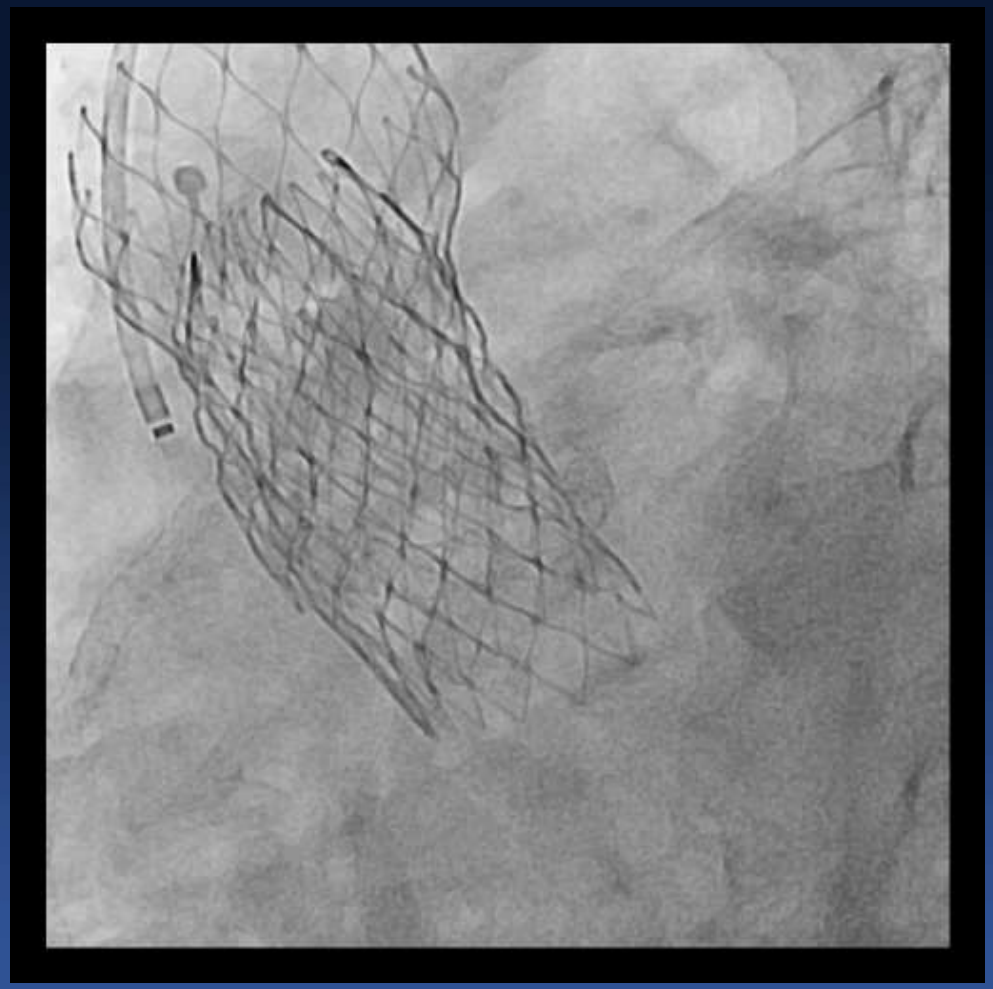

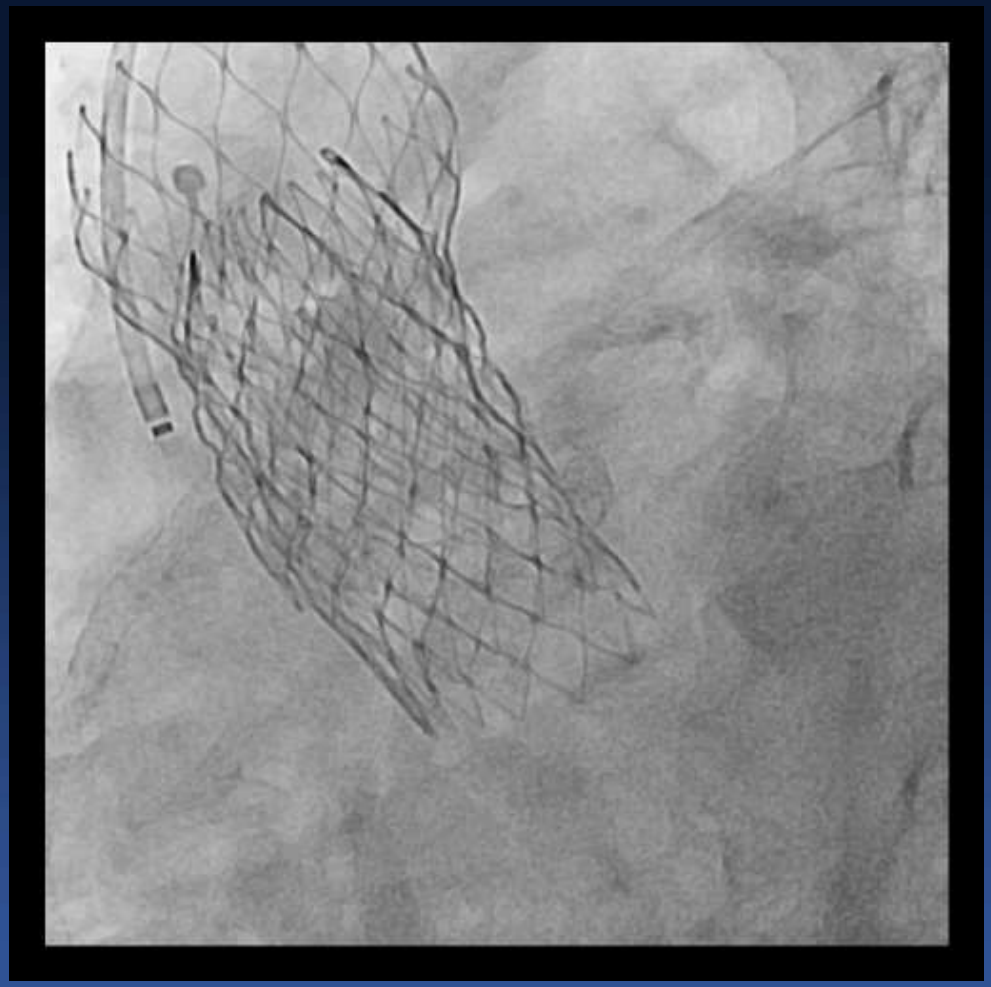

Final Blood Pressure in Sinus

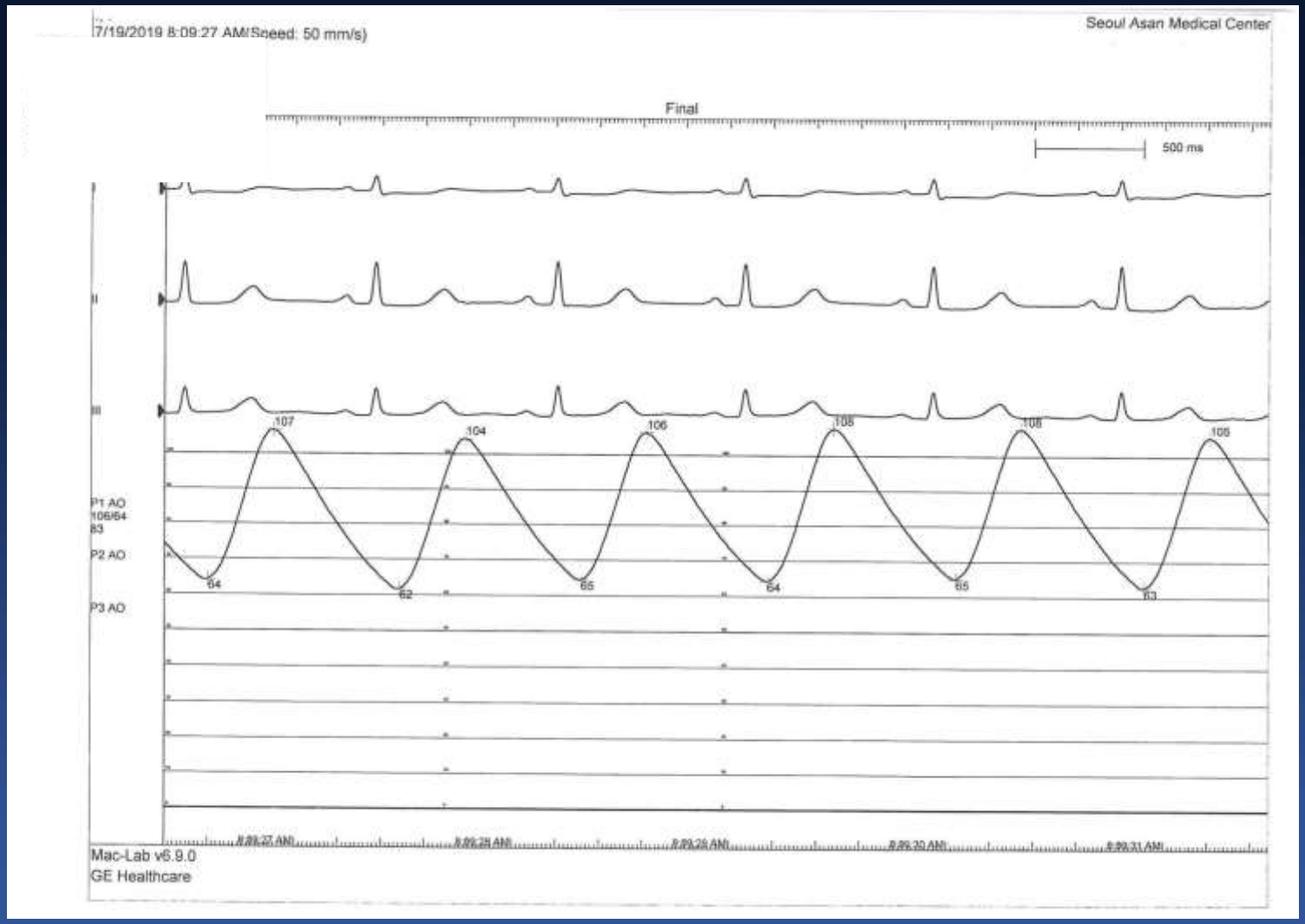

105/65 mmHg

Blood Pressure in Sinus

Before

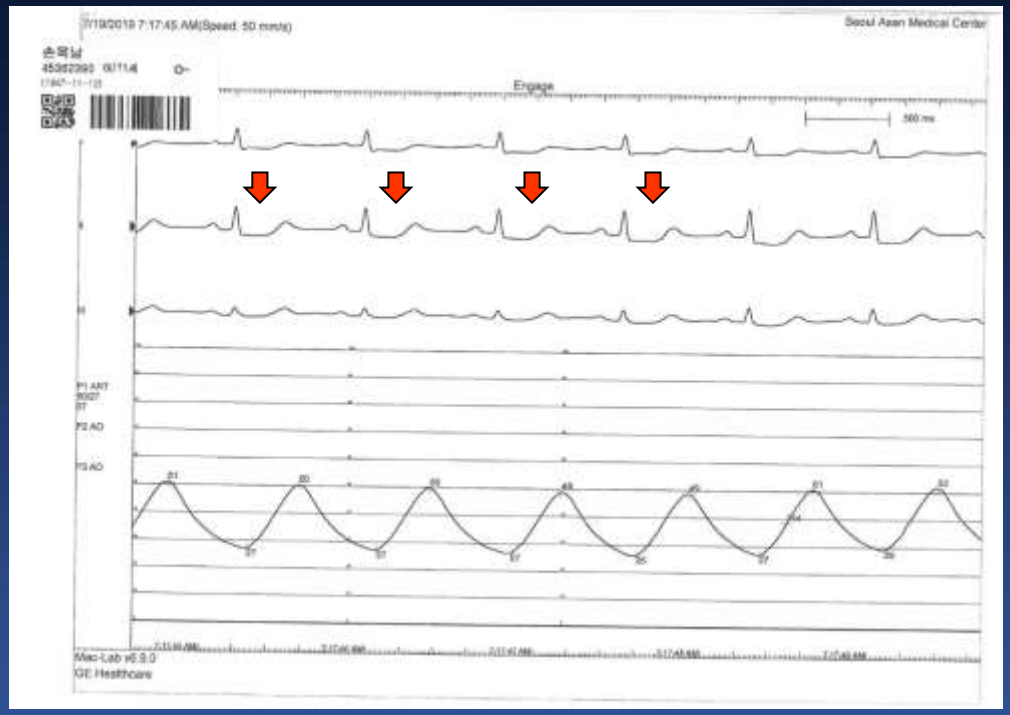

After

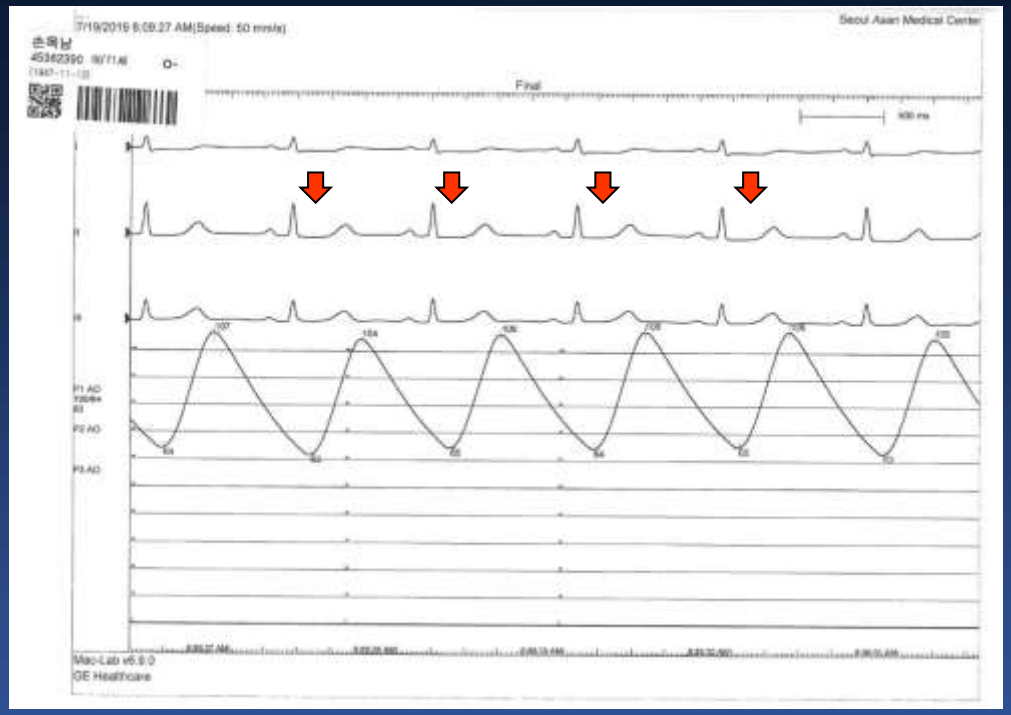

CT image

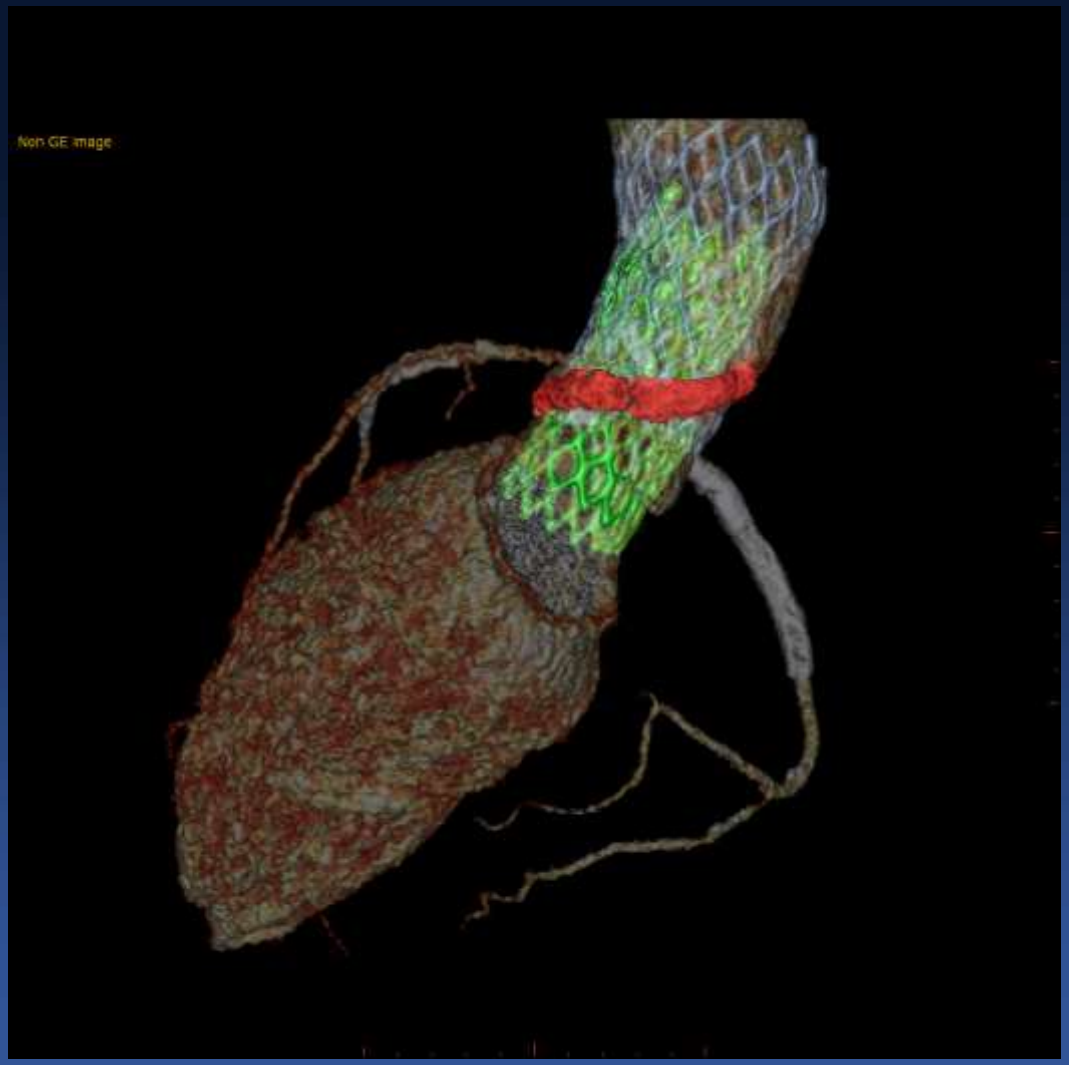

Serial Echocardiogram

Before TAVR

After TAVR

NSTEMI

After Neo-Sinus

CardioVascular Research Foundation
ASAN Medical Center